

BEST PAPERS

5th Edition

2009 - 2022

CONTENTS

DIAGNOSTIC ACCURACY.....	4
<i>MRI/US TARGETED BIOPSY.....</i>	<i>4</i>
<i>3D ULTRASOUND GUIDED BIOPSY.....</i>	<i>17</i>
<i>PRECISION OF THE OBT* FUSION®.....</i>	<i>19</i>
CLINICAL PRACTICE.....	22
<i>TRANSPERINEAL BIOPSY UNDER LOCAL ANESTHESIA.....</i>	<i>22</i>
BEYOND PROSTATE BIOPSY.....	28
<i>DIAGNOSTIC ACCURACY: PET/US TARGETED BIOPSY.....</i>	<i>28</i>
<i>REPEAT BIOPSY FOR ACTIVE SURVEILLANCE STRATEGY.....</i>	<i>31</i>
<i>FOCAL TREATMENT.....</i>	<i>35</i>
BIBLIOGRAPHY.....	38

*ORGAN BASED TRACKING

MRI/US TARGETED BIOPSY

IMPROVEMENT OF THE INTERMEDIATE RISK PROSTATE CANCER SUB-CLASSIFICATION BY INTEGRATING MRI AND FUSION BIOPSY FEATURES

Roumiguie M¹, Lesourd M, Zgheib J, Tollon C, Salin A, Alméras C, Doumerc N, Thoulouzan M, Soulié M, Gautier J-R, Loison G, Assoun J, Vacher A, Aziza R, Bernard Malavaud B, Beauval J-B, Ploussard G.

¹ Department of Urology, CHU Toulouse, Toulouse, France. Department of Urology, La Croix du Sud Hospital, Quint Fonsegrives, France. Department of Urology, Institut Universitaire du Cancer Toulouse - Oncopole, Toulouse, France. Department of Radiology, La Croix du Sud Hospital, Quint Fonsegrives, France. Department of Radiology, Institut Universitaire du Cancer Toulouse - Oncopole, Toulouse, France.

Urol Oncol. 2020

INTRODUCTION: Treatment decision-making for intermediate-risk prostate cancer (CaP) is mainly based on grade and tumor involvement on systematic biopsy. We aimed to assess the added value of multi-parametric magnetic resonance imaging (mpMRI) and targeted biopsy (TB) features for predicting final pathology and for improving the well-established favourable/unfavourable systematic biopsy-based sub-classification.

MATERIALS AND METHODS: From a prospective database of 377 intermediate risk CaP cases, we evaluated the performance of the standard intermediate risk classification (IRC), and the predictive factors for unfavourable disease on final pathology aiming to build a new model. Overall unfavourable disease (OUD) was defined by any pT3-4 and/or pN1 and/or grade group (GG) \geq 3.

RESULTS: The standard IRC was found to be predictive for unfavourable disease in this population. However, in multivariable analysis regression, ECE on mpMRI and GG \geq 3 on TB remained the 2 independent predictive factors for OUD disease (HR = 2.7, P = 0.032, and HR = 2.41, P = 0.01, respectively). By using the new IRC in which unfavorable risk was defined by ECE on mpMRI and/or GG \geq 3 on TB, the proportion of unfavorable cases decreased from 62.3% to 34.1% while better predicting unfavorable disease in RP specimens. The new model displayed a better accuracy than the standard IRC for predicting OUD (AUC: 0.66 vs. 0.55).

CONCLUSIONS: The integration of imaging and TB features drastically improves the intermediate risk sub-classification performance and better discriminates the unfavourable risk group that could benefit from more aggressive therapy such as neo-adjuvant and/or adjuvant treatment, and the favourable group that could avoid over-treatment. External validation in other datasets is needed.

MRI/US TARGETED BIOPSY

ACCURACY OF ELASTIC FUSION BIOPSY IN DAILY PRACTICE: RESULTS OF A MULTICENTER STUDY OF 2115 PATIENTS

Oderda M, Marra G, Albisinni S, Altobelli E, Baco E, Beatrici V, Cantiani A, Carbone A, Ciccariello M, Descotes JL, Dubreuil-Chambardel M, Eldred-Evans D, Fasolis G, Ferriero M, Fiard G, Forte V, Giacobbe A, Kumar P, Lacetera V, Mozer P, Muto G, Papalia R, Pastore A, Peltier A, Piechaud T, Simone G, Roche JB, Roupret M, Rouviere O, Van Velthoven R, Gontero P.

Int J Urol. 2018

OBJECTIVES: To assess the accuracy of KOELIS® fusion biopsy for the detection of prostate cancer and clinically significant prostate cancer in the everyday practice.

METHODS: We retrospectively enrolled 2115 patients from 15 institutions in four European countries undergoing transrectal KOELIS® fusion biopsy from 2010 to 2017. A variable number of target (usually 2-4) and random cores (usually 10-14) were carried out, depending on the clinical case and institution habits. The overall and clinically significant prostate cancer detection rates were assessed, evaluating the diagnostic role of additional random biopsies. The cancer detection rate was correlated to multiparametric magnetic resonance imaging features and clinical variables.

RESULTS: The mean number of targeted and random cores taken were 3.9 (standard deviation 2.1) and 10.5 (standard deviation 5.0), respectively. The cancer detection rate of KOELIS® biopsies was 58% for all cancers and 43% for clinically significant prostate cancer. The performance of additional, random cores improved the cancer detection rate of 13% for all cancers ($P < 0.001$) and 9% for clinically significant prostate cancer ($P < 0.001$). Prostate cancer was detected in 31%, 66% and 89% of patients with lesions scored as Prostate Imaging Reporting and Data System 3, 4 and 5, respectively. Clinical stage and Prostate Imaging Reporting and Data System score were predictors of prostate cancer detection in multivariate analyses. Prostate-specific antigen was associated with prostate cancer detection only for clinically significant prostate cancer.

CONCLUSIONS: KOELIS® fusion biopsy offers a good cancer detection rate, which is increased in patients with a high Prostate Imaging Reporting and Data System score and clinical stage. The performance of additional, random cores seems unavoidable for correct sampling. In our experience, the Prostate Imaging Reporting and Data System score and clinical stage are predictors of prostate cancer and clinically significant prostate cancer detection; prostate-specific antigen is associated only with clinically significant prostate cancer detection, and a higher number of biopsy cores are not associated with a higher cancer detection rate.

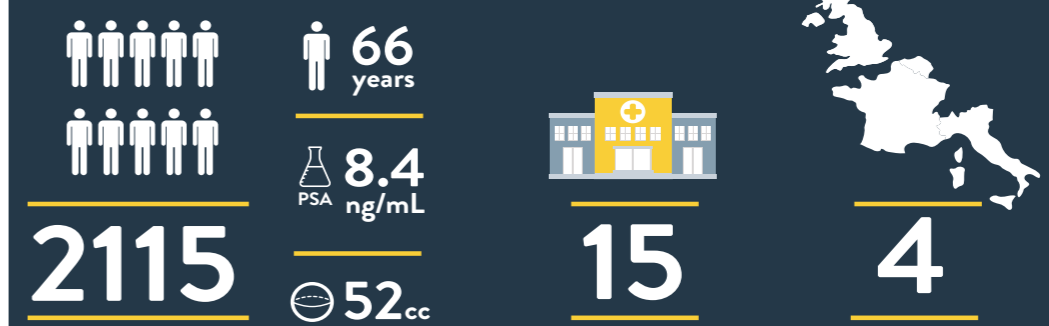
	Target biopsies only	Target + random biopsies	P
PCa detection on biopsy			
CDR	905 (45.6%)	1290 (58.2%)	<0.001
PCa Gleason score			
GS 5	307 (37.3%)	461 (40.1%)	0.14
GS 7	437 (45.7%)	485 (42.8%)	0.25
GS 8-10	162 (16.4%)	197 (17.1%)	0.80
Missing	9	79	
PCa detection according to DRE			
Negative	494 (25.9%)	664 (30.0%)	0.12
Positive	256 (14.1%)	299 (13.0%)	0.17
Missing	215	206	
PCa detection according to size			
<10 mm	226 (10.6%)	325 (14.7%)	0.72
≥10 mm	305 (14.4%)	348 (15.3%)	0.70
Missing	424	577	
PCa detection according to PI-RADS			
3	144 (15.7%)	208 (17.8%)	0.20
4	430 (49.0%)	595 (51.0%)	0.30
5	325 (35.4%)	365 (31.1%)	0.05
Missing	16	94	
PCa detection according to previous biopsy			
Biopsy naïve	321 (12.9%)	430 (18.6%)	0.00
Previous negative biopsies	299 (12.7%)	393 (15.4%)	0.27
Patients in active surveillance	31 (1.4%)	52 (2.0%)	0.16
Missing	264	265	
Clinically significant PCa detection on biopsy			
Clinically significant CDR	716 (33.9%)	909 (43.0%)	<0.001
Clinically significant PCa detection according to PI-RADS			
3	77 (11.3%)	114 (12.7%)	0.29
4	374 (48.9%)	426 (49.4%)	0.84
5	272 (39.8%)	325 (37.4%)	0.36
Missing	33	88	

Figure 1. Biopsy results in terms of PCa and clinically significant PCa detection, comparing target biopsies only with target + random biopsies

Accuracy of elastic fusion biopsy in daily practice Results of a multicenter study of 2115 patients

ODERDA ET AL., INT J UROL, AUGUST 2018

PATIENTS



METHODS

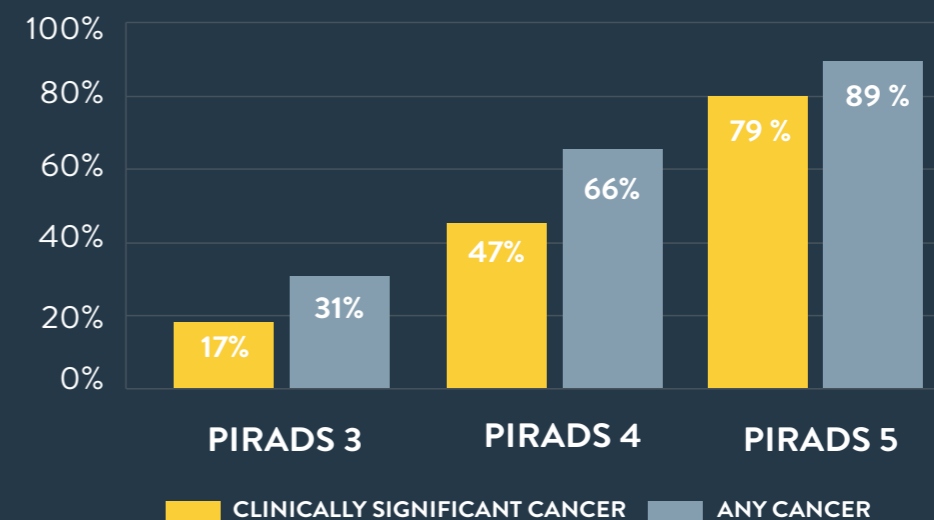
KOELIS PROSTATE MRI/US FUSION

2-4 TARGETED
10-14 RANDOM



RESULTS

DETECTION RATES ACCORDING TO PI-RADS SCORE



MRI/US TARGETED BIOPSY

USE OF PROSTATE SYSTEMATIC AND TARGETED BIOPSY ON THE BASIS OF MULTIPARAMETRIC MRI IN BIOPSY-NAIVE PATIENTS (MRI-FIRST): A PROSPECTIVE, MULTICENTRE, PAIRED DIAGNOSTIC STUDY

Rouvière O, Puech P, Renard-Penna R, Claudon M, Roy C, Mège-Lechevallier F, Decaussin-Petrucci M, Dubreuil-Chambardel M, Magaud L, Remontet L, Ruffion A, Colombel M, Crouzet S, Schott A, Lemaitre L, Rabilloud M, Grenier N, for the MRI-FIRST Investigators*

Lancet Oncol 2018

BACKGROUND: Whether multiparametric MRI improves the detection of clinically significant prostate cancer and avoids the need for systematic biopsy in biopsy-naive patients remains controversial. We aimed to investigate whether using this approach before biopsy would improve detection of clinically significant prostate cancer in biopsy-naive patients.

METHODS: In this prospective, multicentre, paired diagnostic study, done at 16 centres in France, we enrolled patients aged 18–75 years with prostate-specific antigen concentrations of 20 ng/mL or less, and with stage T2c or lower prostate cancer. Eligible patients had been referred for prostate multiparametric MRI before a first set of prostate biopsies, with a planned interval of less than 3 months between MRI and biopsies. An operator masked to multiparametric MRI results did a systematic biopsy by obtaining 12 systematic cores and up to two cores targeting hypoechoic lesions. In the same patient, another operator targeted up to two lesions seen on MRI with a Likert score of 3 or higher (three cores per lesion) using targeted biopsy based on multiparametric MRI findings. Patients with negative multiparametric MRI (Likert score ≤ 2) had systematic biopsy only. The primary outcome was the detection of clinically significant prostate cancer of International Society of Urological Pathology grade group 2 or higher (csPCa-A), analysed in all patients who received both systematic and targeted biopsies and whose results from both were available for pathological central review, including patients who had protocol deviations. This study is registered with ClinicalTrials.gov, number NCT02485379, and is closed to new participants.

FINDINGS: Between July 15, 2015, and Aug 11, 2016, we enrolled 275 patients. 24 (9%) were excluded from the analysis. 53 (21%) of 251 analysed patients had negative (Likert ≤ 2) multiparametric MRI. csPCa-A was detected in 94 (37%) of 251 patients. 13 (14%) of these 94 patients were diagnosed by systematic biopsy only, 19 (20%) by targeted biopsy only, and 62 (66%) by both techniques. Detection of csPCa-A by systematic biopsy (29.9%, 95% CI 24.3–36.0) and targeted biopsy (32.3%, 26.5–38.4) did not differ significantly ($p=0.38$). csPCa-A would have been missed in 5.2% (95% CI 2.8–8.7) of patients had systematic biopsy not been done, and in 7.6% (4.6–11.6) of patients had targeted biopsy not been done. Four grade 3 post-biopsy adverse events were reported (3 cases of prostatitis, and 1 case of urinary retention with haematuria).

INTERPRETATION: There was no difference between systematic biopsy and targeted biopsy in the detection of ISUP grade group 2 or higher prostate cancer; however, this detection was improved by combining both techniques and both techniques showed substantial added value. Thus, obtaining a multiparametric MRI before biopsy in biopsy-naive patients can improve the detection of clinically significant prostate cancer but does not seem to avoid the need for systematic biopsy.

MRI/US TARGETED BIOPSY

MRI-TARGETED OR STANDARD BIOPSY FOR PROSTATE-CANCER DIAGNOSIS

Kasivisvanathan V, M.R.C.S., Rannikko A.S, Borghi M, Panebianco V, Mynderse L.A, Vaarala M.H, Briganti A, Budäus L, Hellawell G, F.R.C.S.(Urol.), Hindley R.G, F.R.C.S.(Urol.), Monique J. Roobol M.J, Scott Eggener S, et al., for the PRECISION Study Group Collaborators*

NEJM 2018

BACKGROUND: Multiparametric magnetic resonance imaging (MRI), with or without targeted biopsy, is an alternative to standard transrectal ultrasonography-guided biopsy for prostate-cancer detection in men with a raised prostate-specific antigen level who have not undergone biopsy. However, comparative evidence is limited.

METHODS: In a multicenter, randomized, noninferiority trial, we assigned men with a clinical suspicion of prostate cancer who had not undergone biopsy previously to undergo MRI, with or without targeted biopsy, or standard transrectal ultrasonography-guided biopsy. Men in the MRI-targeted biopsy group underwent a targeted biopsy (without standard biopsy cores) if the MRI was suggestive of prostate cancer; men whose MRI results were not suggestive of prostate cancer were not offered biopsy. Standard biopsy was a 10-to-12-core, transrectal ultrasonography-guided biopsy. The primary outcome was the proportion of men who received a diagnosis of clinically significant cancer. Secondary outcomes included the proportion of men who received a diagnosis of clinically insignificant cancer.

RESULTS: A total of 500 men underwent randomization. In the MRI-targeted biopsy group, 71 of 252 men (28%) had MRI results that were not suggestive of prostate cancer, so they did not undergo biopsy. Clinically significant cancer was detected in 95 men (38%) in the MRI-targeted biopsy group, as compared with 64 of 248 (26%) in the standard-biopsy group (adjusted difference, 12 percentage points; 95% confidence interval [CI], 4 to 20; $P=0.005$). MRI, with or without targeted biopsy, was noninferior to standard biopsy, and the 95% confidence interval indicated the superiority of this strategy over standard biopsy. Fewer men in the MRI-targeted biopsy group than in the standard-biopsy group received a diagnosis of clinically insignificant cancer (adjusted difference, -13 percentage points; 95% CI, -19 to -7; $P<0.001$).

CONCLUSIONS: The use of risk assessment with MRI before biopsy and MRI-targeted biopsy was superior to standard transrectal ultrasonography-guided biopsy in men at clinical risk for prostate cancer who had not undergone biopsy previously. (Funded by the National Institute for Health Research and the European Association of Urology Research Foundation; PRECISION ClinicalTrials.gov number, NCT02380027.)

MRI/US TARGETED BIOPSY

DETECTION OF PROSTATE CANCER USING MRI-ULTRASONOGRAPHY IMAGE-FUSION TARGETED BIOPSY IN AFRICAN-AMERICAN MEN

Shin T^{1,2}, Smyth T.B, Ukimura O, Ahmadi N, Abreu A.L.d.C, Oishi M, Mimata H, Gill I.S.

¹ USC Institute of Urology, Keck School of Medicine, University of Southern California, Los Angeles, CA, USA.

² Department of Urology, Oita University, Oita, Japan.

BJU Int. 2017

OBJECTIVE: To assess the diagnostic yield of targeted prostate biopsy in African-American (A-A) men using image fusion of multi-parametric magnetic resonance imaging (mpMRI) with real-time transrectal ultrasonography (US).

MATERIALS AND METHODS: We retrospectively analysed 661 patients (117 A-A and 544 Caucasian) who had mpMRI before biopsy and then underwent MRI/US image-fusion targeted biopsy (FTB) between October 2012 and August 2015. The mpMRIs were reported on a 5-point Likert scale of suspicion. Clinically significant prostate cancer (CSPC) was defined as biopsy Gleason score ≥ 7 .

RESULTS: After controlling for age, prostate-specific antigen level and prostate volume, there were no significant differences between A-A and Caucasian men in the detection rate of overall cancer (35.0% vs 34.2%, $P = 0.9$) and CSPC (18.8% vs 21.7%, $P = 0.3$) with MRI/US FTB. There were no significant differences between the races in the location of dominant lesions on mpMRI, and in the proportion of 5-point Likert scoring. In A-A men, MRI/US FTB from the grade 4-5 lesions outperformed random biopsy in the detection rate of overall cancer (70.6% vs 37.2%, $P = 0.003$) and CSPC (52.9% vs 12.4%, $P < 0.001$). MRI/US FTB outperformed random biopsy in cancer core length (5.0 vs 2.4 mm, $P = 0.001$), in cancer rate per core (24.9% vs 6.8%, $P < 0.001$), and in efficiency for detecting one patient with CSPC (mean number of cores needed 13.3 vs 81.9, $P < 0.001$), respectively.

CONCLUSIONS: Our key finding confirms a lack of racial difference in the detection rate of overall prostate cancers and CSPC with MRI/US FTB between A-A and Caucasian men. MRI/US FTB detected more CSPC using fewer cores compared with random biopsy.

MRI/US TARGETED BIOPSY

A RANDOMIZED CONTROLLED TRIAL TO ASSESS AND COMPARE THE OUTCOMES OF TWO-CORE PROSTATE BIOPSY GUIDED BY FUSED MAGNETIC RESONANCE AND TRANSRECTAL ULTRASOUND IMAGES AND TRADITIONAL 12-CORE SYSTEMATIC BIOPSY

Baco E¹, Rud E, Eri LM, Moen G, Vlatkovic L, Svindland A, Eggesbø HB, Ukimura O.

¹Department of Urology, Division for Cancer Medicine, Surgery and Transplantation, Oslo University Hospital



Eur Urol. 2016

PURPOSE: Prostate biopsy guided by computer-assisted fusion of magnetic resonance imaging (MRI) and transrectal ultrasound (TRUS) images (MRI group) has not yet been compared with 12-core random biopsy (RB; control group) in a randomized controlled trial (RCT).

OBJECTIVE: To compare the rate of detection of clinically significant prostate cancer (csPCa) between the two groups.

DESIGN, SETTING, AND PARTICIPANTS: This RCT included 175 biopsy-naïve patients with suspicion for prostate cancer, randomized to an MRI group (n=86) and a control group (n=89) between September 2011 and June 2013.

INTERVENTION: In the MRI group, two-core targeted biopsy (TB) guided by computer-assisted fusion of MRI/TRUS images of MRI-suspicious lesions was followed by 12-core RB. In the control group, both two-core TB for abnormal digital rectal examination (DRE) and/or TRUS-suspicious lesions and 12-core RB were performed. In patients with normal MRI or DRE/TRUS, only 12-core RB was performed.

OUTCOMES MEASUREMENTS AND STATISTICAL ANALYSIS: The detection rates for any cancer and csPCa were compared between the two groups and between TB and RB.

RESULTS AND LIMITATIONS: Detection rates for any cancer (MRI group 51/86, 59%; control group 48/89, 54%; $p=0.4$) and csPCa (38/86, 44% vs 44/89, 49%; $p=0.5$) did not significantly differ between the groups. Detection of csPCa was comparable between two-core MRI/TRUS-TB (33/86, 38%) and 12-core RB in the control group (44/89, 49%; $p=0.2$). In a subset analysis of patients with normal DRE, csPCa detection was similar between two-core MRI/TRUS-TB (14/66, 21%) and 12-core RB in the control group (15/60, 25%; $p=0.7$). Among biopsy-proven csPCas in MRI group, 87% (33/38) were detected by MRI/TRUS-TB. The definition of csPCa was only based on biopsy outcomes.

CONCLUSIONS: Overall csPCa detection was similar between the MRI and control groups. Two-core MRI/TRUS-TB was comparable to 12-core RB for csPCa detection.

PATIENT SUMMARY: Our randomized controlled trial revealed a similar rate of prostate cancer detection between targeted biopsy guided by magnetic resonance imaging (MRI) and transrectal ultrasound (TRUS) and 12-core random biopsy. The traditional 12-core random biopsy may be replaced by two-core MRI/TRUS targeted biopsy for detection of clinically significant prostate cancer.

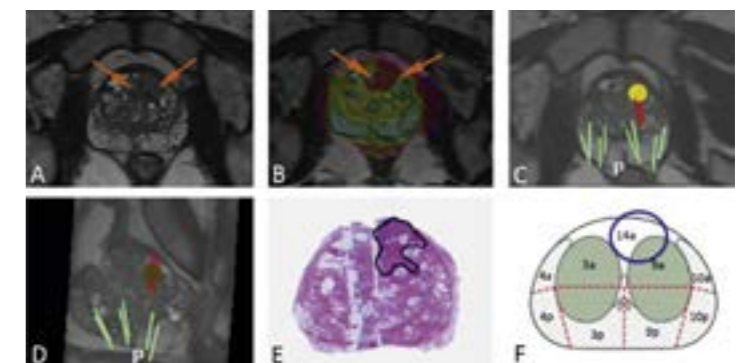


Figure 1. Results for a 67-yr-old man with prostate-specific antigen of 7.2 ng/ml, a normal digital rectal examination, and a prostate volume of 75 ml. Prebiopsy magnetic resonance imaging (MRI) suggested anterior prostate cancer visible on (A) axial T2-weighted images and (B) an apparent diffusion coefficient map with color overlay (arrows). MRI/transrectal ultrasound (TRUS)-targeted biopsy (red bars), as demonstrated by (C) axial and (D) sagittal MRI/TRUS fused images, revealed Gleason 3 + 4 prostate cancer. The cancer core length was 9 and 5 mm (53% and 45% cancer core invasion). The patient was treated with radical prostatectomy. (E) A step-sectioned prostate specimen confirmed pT2 Gleason 3 + 4 prostate cancer. The tumor dimensions were 20 mm T 17 mm T 12 mm (2.2 ml) in the right anterior mid-gland region. (F) Positive biopsies (red bars) and the targeted region (yellow circle) shown in (C) and (D) corresponded to the three-dimensional tumor location in segment 10p.

MRI/US TARGETED BIOPSY

TRANSRECTAL ULTRASOUND-GUIDED PROSTATE BIOPSY FOR CANCER DETECTION: PERFORMANCE OF 2D-, 3D- AND 3D-MRI FUSION TARGETED TECHNIQUES

Klein J¹, De Górski A, Benamran D, Vallee J-P, De Perrot T, Wirth G.J, Iselin C.E.

¹ Division of Urologic Surgery, Department of Surgery, Geneva University Hospital, Geneva, Switzerland.

Urol Int. 2016

INTRODUCTION: The study aimed to evaluate 3 different modalities of transrectal ultrasound (TRUS)-guided prostate biopsies (PBs; 2D-, 3D- and targeted 3D-TRUS with fusion to MRI – T3D). Primary end point was the detection rate of prostate cancer (PC). Secondary end point was the detection rate of insignificant PC according to the Epstein criteria.

MATERIALS AND METHODS: Inclusion of 284 subsequent patients who underwent 2D-, 3D- or T3D PB from 2011 to 2015. All patients having PB for initial PC detection with a serum prostate-specific antigen value ≤ 20 ng/ml were included. Patients with T4 and/or clinical and/or radiological metastatic disease, so as these under active surveillance were excluded.

RESULTS: Patients with T3D PB had a significantly higher detection rate of PC (58 vs. 19% for 2D and 38% for 3D biopsies; $p = 0.001$), with no difference in Gleason score distribution ($p = 0.644$), as well as detection rate of low-risk cancers ($p = 0.914$). Main predictive factor for positive biopsies was the technique used, with respectively a 3- and 8-fold higher detection rate in the 3D- and T3D group. For T3D-PB, there was a significant correlation between radiological cancer suspicion (Prostate Imaging Reporting and Data System Score) and cancer detection rate ($p = 0.02$).

CONCLUSIONS: T3D PB should be preferred over 2D PB and 3D PB in patients with suspected PC as it improves the cancer detection rate.

MRI/US TARGETED BIOPSY

PROSTATE IMAGING REPORTING AND DATA SYSTEM AND LIKERT SCORING SYSTEM: MULTIPARAMETRIC MR IMAGING VALIDATION STUDY TO SCREEN PATIENTS FOR INITIAL BIOPSY

Renard-Penna R¹, Mozer P, Cornud F, Barry-Delongchamps N, Bruguière E, Portalez D, Malavaud B.

¹From the Departments of Radiology (R.R.) and Urology (P.M.), Hôpital Pitié-Salpêtrière, Paris, France; Department of Radiology, Hôpital Cochin, Paris, France (F.C., N.B.); and Departments of Radiology (E.B., D.P.) and Urology (B.M.), Institut Universitaire du Cancer

Radiology. 2015

PURPOSE: To compare the diagnostic performance of the magnetic resonance (MR) imaging-based Prostate Imaging Reporting and Data System (PI-RADS) and a Likert scale in the detection of prostate cancer in a cohort of patients undergoing initial prostate biopsy.

MATERIALS AND METHODS: This institutional review board-approved two-center prospective study included 118 patients with normal digital rectal examination (DRE) results but elevated prostate-specific antigen (PSA) levels (4-20 ng/mL) who were referred for initial prostate biopsies and had one suspicious (Likert scale score, ≥ 3) focus at prebiopsy 1.5-T multiparametric MR imaging performed with T2-weighted, diffusion-weighted [DW], and dynamic contrast material-enhanced imaging. Targeted core biopsies and random systematic core biopsies were performed. The elementary unit for analysis was the core. Relationships were assessed by using the Mann-Whitney U test. Yates corrected and Pearson χ^2 tests were used to evaluate categorical variables. A training set was randomly drawn to construct the receiver operating characteristic curves for the summed PI-RADS scores and for the Likert scale scores. The thresholds to recommend biopsy were obtained from the Youden J statistics and were tested in the remaining validation set in terms of predictive characteristics. Interobserver variability was analyzed by using weighted κ statistics in a random set of 50 patients.

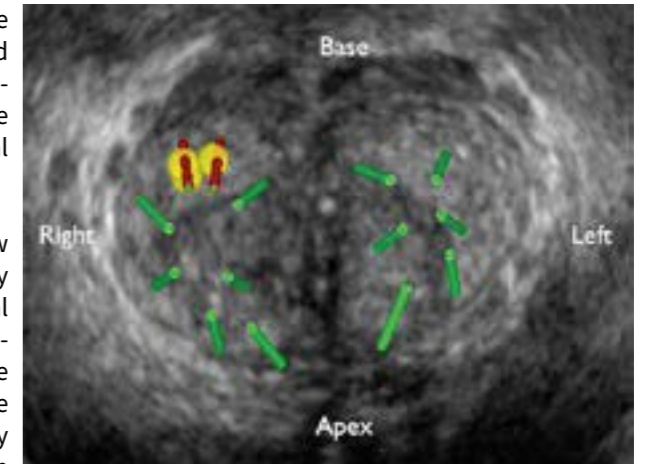


Figure 1. Three-dimensional transrectal US fused image shows the location in the 1a sector of a suspicious focus (yellow; summed PI-RADS score at multiparametric MR imaging, 14) that was targeted by two targeted (red) cores in complement to 12 random (green) systematic cores in a 61-mL prostate.

RESULTS: Higher T2-weighted, DW, and dynamic contrast-enhanced imaging PI-RADS scores were observed in areas that yielded cancer-positive cores. The percentage of positive cores increased with the sum of scores aggregated in five classes as follows: For summed PI-RADS scores of 3-5, the percentage of positive cores was 2.3%; for scores of 6-8, it was 5.8%; for scores of 9 or 10, it was 24.7%; for scores of 11 or 12, it was 51.8%; and for scores of 13-15, it was 72.1% (P for trend, $< .0001$). For the threshold of summed PI-RADS scores of 9 or greater, sensitivity was 86.6%, specificity was 82.4%, the positive predictive value was 52.4%, the negative predictive value was 96.5%, and accuracy was 83.2%. The respective data for Likert scale scores of 3 or greater were 93.8%, 73.6%, 44.3%, 98.1%, and 73.3%. Good interobserver agreement was observed for the Likert scale ($\kappa = 0.80$) and the summed PI-RADS ($\kappa = 0.73$) scoring systems.

CONCLUSIONS: PI-RADS provided the site-specific stratified risk of cancer-positive cores in biopsy-naïve men with normal DRE results and elevated PSA levels. There was no significant difference between summed PI-RADS scores of 9 or greater and Likert scale scores of 3 or greater in the detection of cancer in the peripheral zone.

MRI/US TARGETED BIOPSY

FIRST ROUND OF TARGETED BIOPSIES USING MAGNETIC RESONANCE IMAGING/ULTRASONOGRAPHY FUSION COMPARED WITH CONVENTIONAL TRANSRECTAL ULTRASONOGRAPHY-GUIDED BIOPSIES FOR THE DIAGNOSIS OF LOCALISED PROSTATE CANCER

Mozer P¹, Rouprêt M, Le Cossec C, Granger B, Comperat E, de Gorski A, Cussenot O, Renard-Penna R.

¹Academic Department of Urology, AP-HP, Hôpital Pitié-Salpêtrière, Paris, France; UPMC University of Paris 06, Institut des Systèmes Intelligents et de Robotique.

BJUI. 2014

OBJECTIVE: To assess the accuracy of magnetic resonance imaging (MRI)/transrectal ultrasonography (TRUS) fusion to guide first-round biopsies in the diagnosis of localised prostate cancer (PCa) in men with a prostate-specific antigen (PSA) ≤ 10 ng/mL.

PATIENTS AND METHODS: A prospective study was conducted on men who met the following criteria: first-round biopsy, multiparametric MRI (mpMRI) showing a lesion with a Likert score ≥ 2 and a PSA < 10 ng/mL. All men underwent an extended 12-core protocol plus a protocol of two or three targeted cores on the mpMRI index lesion. The UroStation (KOELIS®, Grenoble, France) and a V10 ultrasound system with an end-fire three-dimensional TRUS transducer were used for the fusion imaging procedure. Significant PCa was defined as: at least one core with a Gleason score of 3 + 4 or 6 with a maximum cancer core length ≥ 4 mm.

RESULTS: A total of 152 men, whose median PSA level was 6 ng/mL, were included in the study. The proportion of positive cores was significantly higher with the targeted-core protocol than with the extended 12-core protocol ($P < 0.001$). The proportion of men with clinically significant PCa was higher with the targeted-core protocol than with the extended 12-core protocol ($P = 0.03$). The proportion of patients having at least one positive biopsy (targeted-core protocol) was significantly different among the Likert score categories ($P < 0.001$).

CONCLUSIONS: For the first round of biopsies, MRI/TRUS-fusion targeted biopsies detected more men with clinically significant PCa than did standard extended 12-core biopsy alone.

	Extended 12-core protocol	Targeted-core protocol	P
Cores positive for clinically significant PCa, %	7.5	31	<0.001
Men with clinically significant PCa detected, %	37	45	0.03
Median number of cores taken per diagnosis of clinically significant PCa	12	2	<0.001
Median (IQR) length of positive cores, mm	4 (2-8)	8 (5-18)	<0.001

PCa, prostate cancer; IQR, interquartile range.

Table 1. Comparisons of the two biopsy protocols (N = 152).

MRI/US TARGETED BIOPSY

DYNAMIC EVALUATION OF MRI-TARGETED, SYSTEMATIC AND COMBINED BIOPSY FOR PROSTATE CANCER DIAGNOSIS THROUGH 10 YEARS OF PRACTICE IN A SINGLE INSTITUTION

L. Lenfant, A. Beaugerie, R. Renard-Penna, T. Seisen, M. Rouprêt, P. Conort, E. Comperat, P. Rouvier, E. Chartier-Kastler, P. Mozer

Hôpital Pitié-Salpêtrière, Paris, France

WJOU 2018

PURPOSE: To perform a dynamic evaluation of the prostate cancer (PCa) detection rate according to the biopsy strategy over 10 years of practice in a single institution that pioneered MRI-targeted fusion biopsy (MRI-TB).

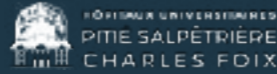METHODS: This stage 4 IDEAL study prospectively included all consecutive patients who underwent transrectal prostate biopsy for clinically suspected PCa between January 2010 and November 2020. Patients with positive MRI (PIRADS score ≥ 3) underwent both MRI-TB and systematic biopsy (SB) while those with negative MRI (PIRADS score < 3) underwent SB only. The main outcome was the evolution of the detection rate of clinically relevant PCa (csPCa; grade ≥ 2). The secondary outcome was the change in PCa detection rate according to the biopsy method.

RESULTS: A total of 2942 men underwent prostate MRI and a prostate biopsy: 2322 underwent MRI-TB and 620 had SB only. The detection rate of csPCa increased 2.5-fold from 23 to 58%. The detection rate of PCa and csPCa was significantly higher in patients who underwent MRI-TB compared to those who underwent SB only (67% vs. 52% and 40% vs. 32%, respectively ($P < 0.001$ for both comparisons)). The number of csPCa diagnosed by MRI-TB increased linearly over the study period and represented the majority of PCa diagnoses after 2016.

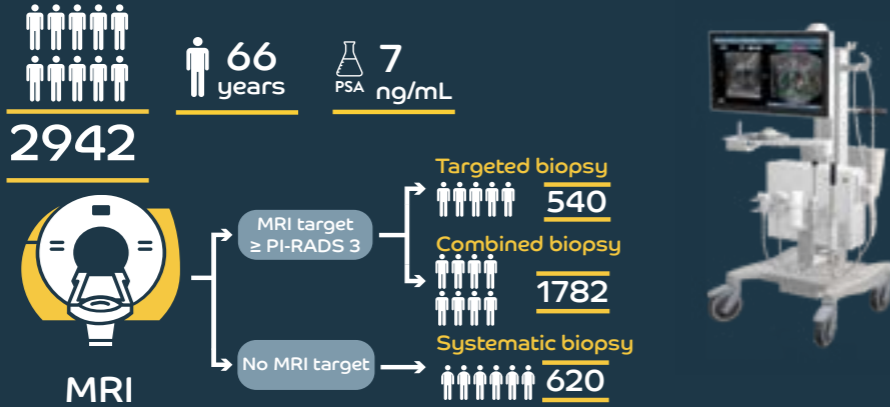
CONCLUSIONS: Implementation of MRI-TB in patients with positive MRI led to improved detection of csPCa.

Dynamic evaluation of MRI-targeted, systematic and combined biopsy for prostate cancer diagnosis through 10 years of practice in a single institution

LENFANT ET AL, WORLD JOURNAL OF UROLOGY (APRIL 2022)

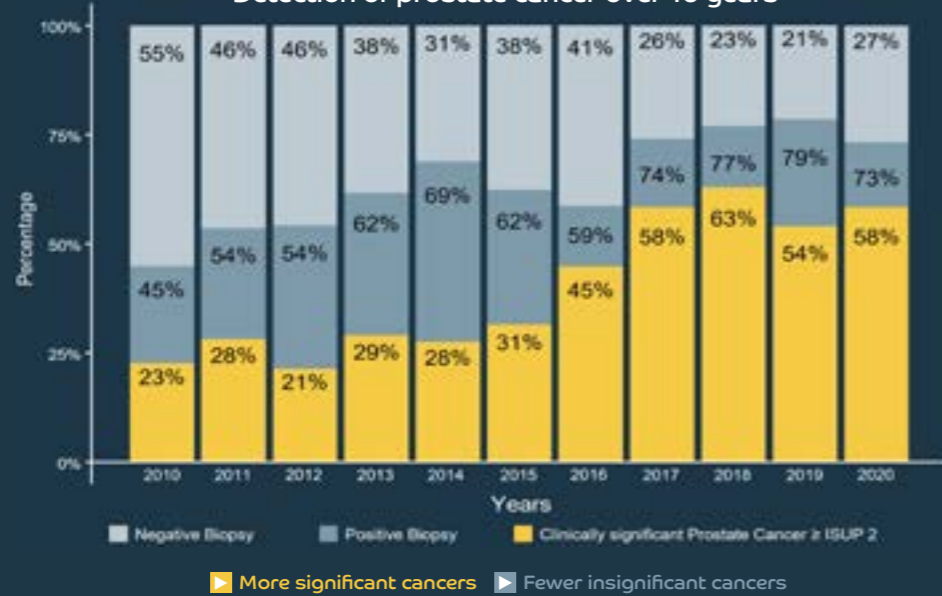


PATIENTS & METHODS



RESULTS

Detection of prostate cancer over 10 years



- Clinically significant cancer detection x2.5 in 10 years from 23% to 58%.
- Clinically insignificant cancer decreases to <20% ratio by ruling out negative MRI in 2015.
- Results obtained with more targeted, less systematic biopsy cores over years.

KEY TAKE AWAY

- A new prostate biopsy standard has been validated over 10 years in a single academic institution.
- Evidencing the efficacy of a KOELIS-guided targeted+systematic scheme after positive MRI.
- In maximizing detection of clinically significant cancer and minimizing insignificant cancer.



KCOM_2204_CU.3_V1.EN

MRI/US TARGETED BIOPSY

TECHNIQUES AND OUTCOMES OF MRI-TRUS FUSION PROSTATE BIOPSY

Masatomo Kaneko, Dordaneh Sugano, Amir H. Lebastchi, Vinay Duddalwar, Jamal Nabhani, Christopher Haiman, Inderbir S. Gill, Giovanni E. Cacciamani, Andre Luis Abreu

Department of Urology, Graduate School of Medical Science, Kyoto Prefectural University of Medicine, Kyoto, Japan

NEJM 2018

PURPOSE OF REVIEW: The goal of this study is to review recent findings and evaluate the utility of MRI transrectal ultrasound fusion biopsy (FBx) techniques and discuss future directions.

RECENT FINDINGS: FBx detects significantly higher rates of clinically significant prostate cancer (csPCa) than ultrasound-guided systematic prostate biopsy (SBx), particularly in repeat biopsy settings. FBx has also been shown to detect significantly lower rates of clinically insignificant prostate cancer. In addition, a dedicated prostate MRI can assist in more accurately predicting the Gleason score and provide further information regarding the index cancer location, prostate volume, and clinical stage. The ability to accurately evaluate specific lesions is vital to both focal therapy and active surveillance, for treatment selection, planning, and adequate follow-up.

SUMMARY: FBx has been demonstrated in multiple high-quality studies to have improved performance in diagnosis of csPCa compared to SBx. The combination of FBx with novel technologies including radiomics, prostate-specific membrane antigen positron emission tomography (PSMA PET), and high-resolution micro-ultrasound may have the potential to further enhance this performance.

3D ULTRASOUND GUIDED BIOPSY

3D VERSUS 2D SYSTEMATIC TRANSRECTAL ULTRASOUND-GUIDED PROSTATE BIOPSY: HIGHER CANCER DETECTION RATE IN CLINICAL PRACTICE

Alexandre Peltier^{1,2}, Fouad Aoun^{1&2}, Fouad El-Khoury,¹ Eric Hawaux,¹ Ksenija Limani,¹ Krishna Narahari,¹ Nicolas Sirtaine,³ and Roland Van Velthoven^{1,2}

¹ Department of Urology, Jules Bordet Institute, 1 Rue Héger-Bordet, 1000 Brussels, Belgium

² Université Libre de Bruxelles, 50 Franklin Roosevelt Avenue, 1050 Brussels, Belgium

³ Department of Anatomopathology, Jules Bordet Institute, 1 Rue Héger-Bordet, 1000 Brussels, Belgium

Hindawi. 2013

PURPOSE: To compare prostate cancer detection rates of extended 2D versus 3D biopsies and to further assess the clinical impact of this method in day-to-day practice.

MATERIALS AND METHODS: We analyzed the data of a cohort of 220 consecutive patients with no prior history of prostate cancer who underwent an initial prostate biopsy in daily practice due to an abnormal PSA and/or DRE using, respectively, the classical 2D and the new 3D systems. All the biopsies were done by a single experienced operator using the same standardized protocol.

RESULTS: There was no significant difference in terms of age, total PSA, or prostate volume between the two groups. However, cancer detection rate was significantly higher using the 3D versus the 2D system, 50% versus 34% ($P < 0.05$). There was no statistically significant difference while comparing the 2 groups in term of nonsignificant cancer detection.

CONCLUSIONS: There is reasonable evidence demonstrating the superiority of the 3D-guided biopsies in detecting prostate cancers that would have been missed using the 2D extended protocol.

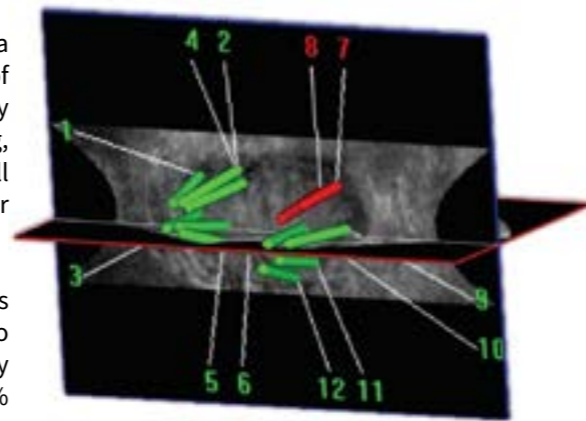


Figure 1. 3D trajectory visualization after biopsy along with mapping and cartography.

3D ULTRASOUND GUIDED BIOPSY

MAPPING OF TRANSRECTAL ULTRASONOGRAPHIC PROSTATE BIOPSIES: QUALITY CONTROL AND LEARNING CURVE ASSESSMENT BY IMAGE PROCESSING

Mozer P¹, Baumann M, Chevreau G, Moreau-Gaudry A, Bart S, Renard-Penna R, Comperat E, Conort P, Bitker MO, Chartier-Kastler E, Richard F, Troccaz J.

¹Department of Urology, Assistance Publique-Hôpitaux de Paris, Paris, France

J US Med. 2009

PURPOSE: Mapping of transrectal ultrasonographic (TRUS) prostate biopsies is of fundamental importance for either diagnostic purposes or the management and treatment of prostate cancer, but the localization of the cores seems inaccurate. Our objective was to evaluate the capacities of an operator to plan transrectal prostate biopsies under 2-dimensional TRUS guidance using a registration algorithm to represent the localization of biopsies in a reference 3-dimensional ultrasonographic volume.

Thirty-two patients underwent a series of 12 prostate biopsies under local anesthesia performed by 1 operator using a TRUS probe combined with specific third-party software to verify that the biopsies were indeed conducted within the planned targets.

RESULTS: The operator reached 71% of the planned targets with substantial variability that depended on their localization (100% success rate for targets in the middle and right parasagittal parts versus 53% for targets in the left lateral base). Feedback from this system after each series of biopsies enabled the operator to significantly improve his dexterity over the course of time (first 16 patients: median score, 7 of 10 and cumulated median biopsy length in targets of 90 mm; last 16 patients, median score, 9 of 10 and a cumulated median length of 121 mm; $P = .046$).

CONCLUSIONS: In addition to being a useful tool to improve the distribution of prostate biopsies, the potential of this system is above all the preparation of a detailed «map» of each patient showing biopsy zones without substantial changes in routine clinical practices.

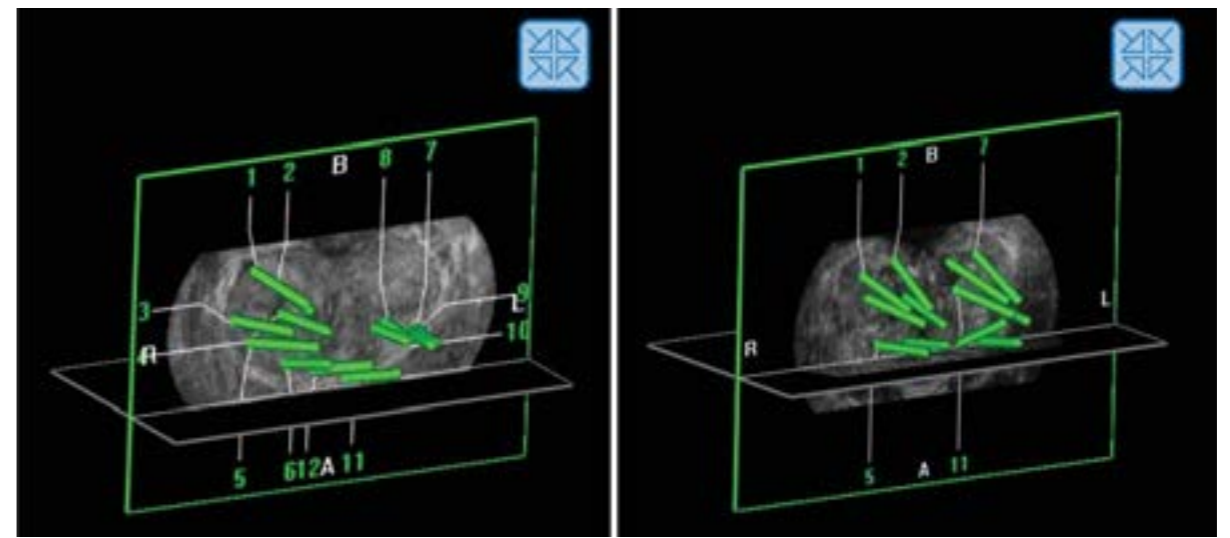


Figure 1. Examples of biopsy distributions in the coronal plane for 2 different patients. Left, Patient from the first group, left base not sampled. Right, Patient from the second group, good sampling. A indicates apex; B, base; L, left; and R, right.

PRECISION OF THE OBT FUSION®

PRECISION MATTERS IN MR IMAGING-TARGETED PROSTATE BIOPSIES: EVIDENCE FROM A PROSPECTIVE STUDY OF COGNITIVE AND ELASTIC FUSION REGISTRATION TRANSRECTAL BIOPSIES.

Cornud F¹, Roumiguié M¹, Barry de Longchamps N¹, Ploussard G¹, Bruguière E², Portalez D², Malavaud B².

¹Departments of Radiology (F.C.) and Urology (N.B.d.L.), Hôpital Cochin, Université Paris Descartes, Paris, France
²Institut Universitaire du Cancer, Toulouse

Radiology 2018

PURPOSE: To measure the precision in placement of a biopsy needle in a magnetic resonance (MR) imaging-detected target with transrectal ultrasonography (US), to document the clinical relevance of precision, and to report on the precision of cognitive and software-based registrations.

PATIENTS AND METHODS: This prospective study was approved by the institutional review board and performed between June 2013 and September 2013. Patients provided informed verbal consent. Two cores each were obtained with cognitive and fusion techniques in 88 patients with a Prostate Imaging Reporting and Data System version 1 score of at least 3. Precision was measured with Euclidian geometry by using the Digital Imaging and Communications in Medicine archives of the biopsy as the distance from the core to the center (dCC) and the distance from the core to the surface of the target modeled as a sphere. To address clustering of data from multiple cores in the same patients, analyses of precision focused on the best shot for a patient or a technique. The Welch unequal variance t test and Yates corrected x2 test were used as appropriate.

RESULTS: Mean precision was 2.5 mm (95% confidence interval: 1.8 mm, 3.3 mm). Positive cores were closer to the center than were negative cores (dCC: 1.7 mm vs 3.1 mm, respectively; P = .025). More cancers were detected with on-target than off-target cores (33 of 71 cores [46.5%] vs three of 17 cores [17.6%]; P = .03). Cores obtained with the fusion technique achieved a higher precision than did cores obtained with the cognitive technique (dCC: 2.8 mm vs 7.1 mm, respectively; P < .0001). Targeted cores demonstrated cancer in 44 patients. Fewer cancers were detected with the cognitive technique than with the fusion technique (31 of 44 patients [70.5%] vs 40 of 44 patients [90.9%]; P = .03).

CONCLUSIONS: A deformable MR imaging/transrectal US image registration system achieved a higher precision and depicted cancer in more patients than did the cognitive freehand technique. was probably best than PET choline for detecting prostate cancer but it could be complementary.

Precision Matters in MR Imaging-targeted Prostate Biopsies

CORNUD ET AL., RADIOLOGY, MAY 2018

PATIENTS

88
63 years
8.2 PSA ng/mL
40cc

UROLOGISTS

>10 years experience
COGNITIVE MRI FUSION & ELASTIC MRI FUSION

METHODS

TRANSRECTAL BIOPSY → 2 COGNITIVE CORES → 2 ELASTIC FUSION CORES

ON-TARGET vs OFF-TARGET

CANCER TISSU SAMPLE

OFF-TARGET	2.5mm
ON-TARGET	7mm

CHANCE OF DEMONSTRATING CANCER

ON-TARGET	46.5%
OFF-TARGET	17.6%

COGNITIVE vs ELASTIC FUSION

% OF POSITIVE CORES

COGNITIVE	70.5%
ELASTIC FUSION	90.9%

LOCATION OF TARGETS	PRECISION Distance from the core to the center of the target		INFORMATION Distance from the core to the surface of the target	
	COGNITIVE CORES (n=88)	FUSION CORES (n=88)	COGNITIVE CORES (n=88)	FUSION CORES (n=88)
BASE	8.4mm	3.6mm	4.0mm	-0.8mm
MID	6.6mm	2.5mm	2.6mm	-1.5mm
APEX	6.3mm	2.3mm	1.6mm	-2.4mm

© KOEHLIS 2018 - KNIF MAY 2018

PRECISION OF THE OBT FUSION®

TRUS-MRI IMAGE REGISTRATION: A PARADIGM SHIFT IN THE DIAGNOSIS OF SIGNIFICANT PROSTATE CANCER

Cornud F¹, Brolis L, Delongchamps NB, Portalez D, Malavaud B, Renard-Penna R, Mozer P.¹Department of Radiology, Hôpital Cochin, Paris, France

Abdom Imaging. Dec 2013

ABSTRACT: Accuracy of multiparametric MRI has greatly improved the ability of localizing tumor foci of prostate cancer. This property can be used to perform a TRUS-MR image registration, new technological advance, which allows for an overlay of an MRI onto a TRUS image to target a prostate biopsy toward a suspicious area. Three types of registration have been developed: cognitive-based, sensor-based, and organ-based registration. Cognitive registration consists of aiming a suspicious area during biopsy with the knowledge of the lesion location identified on multiparametric MRI. Sensor-based registration consists of tracking in real time the TRUS probe with a magnetic device, achieving a global positioning system which overlays in real-time prostate image on both modalities. Its main limitation is that it does not take into account prostate and patient motion during biopsy. Two systems (Artemis and Uronav) have been developed to partially circumvent this drawback. Organ-based registration (KOELIS®) does not aim to track the TRUS probe, but the prostate itself to compute in a 3D acquisition the TRUS prostate shape, allowing for a registration with the corresponding 3D MRI shape. This system is not limited by prostate/patient motion and allows for a deformation of the organ during registration. Pros and cons of each technique and the rationale for a targeted biopsy only policy are discussed.

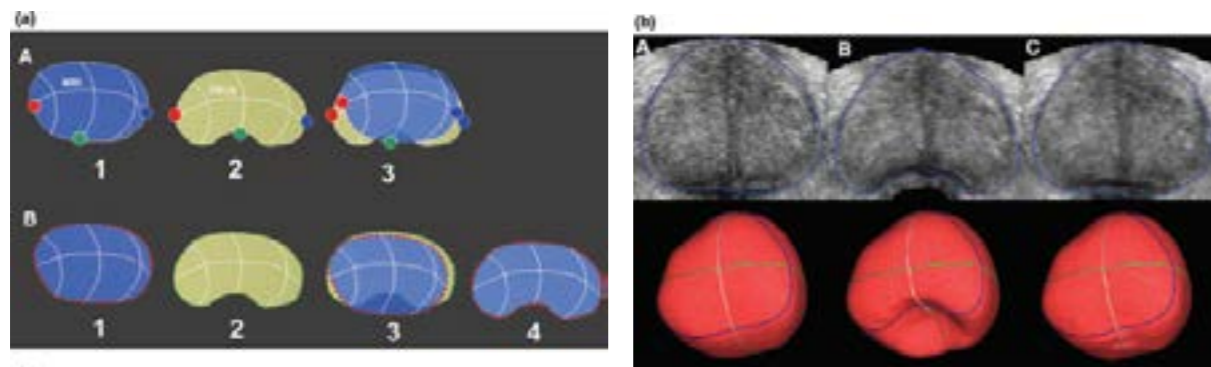


Figure 1. Diagram explaining differences between rigid (non deformable) and elastic (deformable) registration.

(a) Rigid registration. A Three points have been placed on the MRI (1) and on TRUS prostate contour (2). Differences in prostate shape and deformation do not allow for an accurate prostate overlay after rigid registration (3). B Elastic deformation with surface-based registration and organ deformation. Multiple points have been placed on MRI and TRUS prostate contour (1, 2). This first step is a rigid registration which still lacks accuracy owing to the differences in prostate shape (3). An algorithm allows for a deformation of the MRI prostate shape to allow for an accurate registration (4).

(b) Demonstration of the efficiency of elastic deformation. A The original shape of the prostate with its correspondent 3D shape (red image, lower row). B Induction with a mathematical model of a posterior deformation of the prostate (10-mm-diameter sphere to simulate TRUS probe insertion). C After activation of the elastic registration software, the original 3D shape has been rebuilt.

TRANSPERINEAL BIOPSY UNDER LOCAL ANESTHESIA

MULTICENTER TRANSPERINEAL MRI-TRUS FUSION GUIDED OUTPATIENT CLINIC PROSTATE BIOPSIES UNDER LOCAL ANESTHESIA

Jacewicz M¹, Günzel K, Rud E, Lauritzen P.M, Galtung K.F, Hinz S, Baco E.¹Department of Urology, Oslo University Hospital, Oslo, Norway

Urol Oncol. 2020

INTRODUCTION: Transperineal Prostate biopsies (TPBx) are usually performed under general anesthesia without image fusion. This study aimed to evaluate prostate cancer (Pca) detection rates (CDR), pain, and adverse events using a novel, free-hand TPBx technique, based on elastic fusion of magnetic resonance imaging (MRI) and transrectal ultrasound (TRUS) under local anesthesia.

MATERIALS AND METHODS: This multicenter retrospective study included all consecutive patients scheduled for a TPBx. All had clinical suspicion of Pca, active surveillance scheduled for a re-biopsy, or suspicion of local recurrence after previous treatment. Bi-parametric or multiparametric MRI was performed in all patients and classified as positive in the case of Prostate Imaging-Reporting and Data System (PIRADS) suspicion ≥ 3 . At least 1 targeted TPBx was realized from each PIRADS ≥ 3 index lesion. Six to 12 systematic random TPBx were done in patients with negative MRI. All biopsies were performed under local anesthesia in an outpatient clinic with MRI-TRUS fusion and the 3D navigation system KOELIS TRINITY® PERINE™ (KOELIS®, France). Any- and clinically significant Pca (csPca) (ISUP gr. ≥ 2) was recorded. Biopsy-related pain and adverse events were reported according to a visual analogue score of 0–10.

RESULTS: In total, 377 patients were included for analyses. The mean age was 67 years (95% Confidence Interval: 66–68) and the median prostate-specific antigen was 7.2 ng/ml (interquartile range [IQR] 4.8–11.0). MRI was negative in 6% and positive in 94%. The median MRI prostate volume was 43 ml (IQR 31–60) and the median MRI index tumor volume was 0.9 ml (IQR 0.5–2.1). The median number of TPBx was 4 (IQR 3–4). The overall detection of any- and csPca was 64% and 52%, respectively. The overall CDR according to PIRADS 3, 4, and 5 was 30%, 70%, and 94%, respectively. In patients with negative MRI, any- and csPca was detected in 23% and 9%, respectively. The median visual analogue score score was 2 (IQR 1–3, range 0–7). Two patients (0.5%) developed postbiopsy infection, of which one developed urosepsis. Treatment requiring haematuria or urinary retention did not occur.


CONCLUSIONS: Free-hand MRI/TRUS fusion-guided and systematic random TPBx in LA is a feasible, safe, and well-tolerated technique for diagnosing Pca.

Multicenter **transperineal MRI-TRUS fusion** guided outpatient clinic prostate **biopsy** under local anesthesia

JACEWICZ ET AL., INT J UROL, JULY 2020

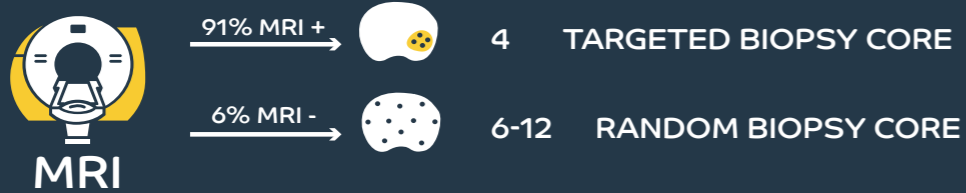
PATIENTS

DAILY CLINICAL PRACTICE



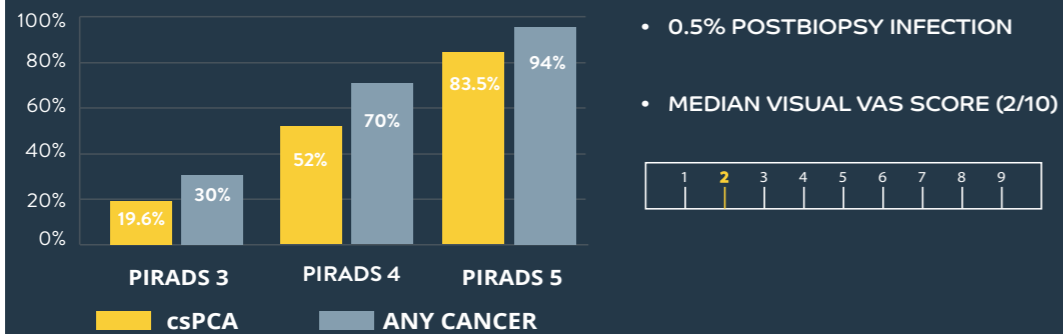
METHODS

Transperineal biopsy - KOELIS MRI/US fusion



RESULTS

DETECTION RATE OF ANY CANCER & CSPCA



KEY TAKE AWAY

- HIGHER DETECTION RATE
- LOW POSTBIOPSY INFECTION RATE
- WELL-TOLERATED TECHNIQUE



TRANSPERINEAL BIOPSY UNDER LOCAL ANESTHESIA

MANAGING DISCORDANT FINDINGS BETWEEN MULTIPARAMETRIC MAGNETIC RESONANCE IMAGING AND TRANSRECTAL MAGNETIC RESONANCE IMAGING-DIRECTED PROSTATE BIOPSY—THE KEY ROLE OF MAGNETIC RESONANCE IMAGING-DIRECTED TRANSPERINEAL BIOPSY

Bajeot A-N, Covin B, Meyrignac O, Pericart S, Aziza R, Portalez D, Graff-Cailleaud P, Ploussard G, Roumiguié M, Malavaud B

Department of Urology, Institut Universitaire du Cancer, Toulouse, France.

Euro Urol Onco 2021

BACKGROUND: Discordant findings between multiparametric magnetic resonance imaging (mpMRI) and transrectal image-guided biopsies of the prostate (TRUS-P) may result in inadequate risk stratification of localized prostate cancer.

OBJECTIVE: To assess transperineal image-guided biopsies of the index target (TPER-IT) in terms of disease reclassification and treatment recommendations.

DESIGN, SETTING, AND PARTICIPANTS: Cases referred for suspicion or treatment of localized prostate cancer were reviewed in a multidisciplinary setting, and discordance was characterized into three scenarios: type I—negative biopsies or International Society of Urological Pathology (ISUP) grade 1 cancer in Prostate Imaging Reporting and Data System (PI-RADS) ≥ 4 index target (IT); type II—negative biopsies or ISUP grade 1 cancer in anterior IT; and type III— < 3 mm stretch of cancer in PI-RADS ≥ 3 IT. Discordant findings were characterized in 132/558 (23.7%) patients after TRUS-P. Of these patients, 102 received reassessment TPER-IT.

OUTCOME MEASUREMENTS AND STATISTICAL ANALYSIS: The primary objective was to report changes in treatment recommendations after TPER-IT. Therefore, cores obtained by primary TRUS-P and TPER-IT were analyzed in terms of cancer detection, ISUP grade, and Cambridge Prognostic Group classification using descriptive statistics.

RESULTS AND LIMITATIONS: TPER-IT biopsies that consisted of fewer cores than the initial TRUS-P (seven vs 14, $p < 0.0001$) resulted in more cancer tissue materials for analysis (56 vs 42.5 mm, $p = 0.0003$). As a result, 40% of patients initially considered for follow-up (12/30) and 49% for active surveillance (30/61) were reassigned after TPER-IT to surgery or intensity-modulated radiotherapy.

CONCLUSIONS: Nonconcordance between pathology and imaging was observed in a significant proportion of patients receiving TRUS-P. TPER-IT better informed the presence and grade of cancer, resulting in a significant impact on treatment recommendations. A multidisciplinary review of mpMRI and TRUS-P findings and reassessment TPER-IT in type I–II discordances is recommended.

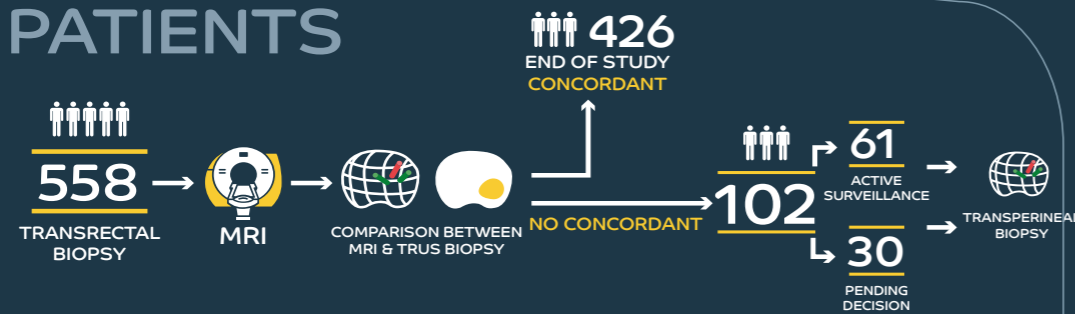
PATIENT SUMMARY: In this report, patients with suspicious imaging of the prostate, but no or well-differentiated cancer on transrectal image-guided -biopsies, were offered transperineal image-guided biopsies for reassessment. We found that a large share of these had a more aggressive cancer than initially suspected. We conclude that discordant results warrant reassessment transperineal image-guided biopsies as these may impact disease risk classification and treatment recommendations.

KOELIS 2018 - KNUF AUGUST 2018

Managing **discordant findings** between multiparametric magnetic resonance imaging and transrectal magnetic resonance imaging-directed **prostate biopsy**
 The key role of magnetic resonance imaging-directed **transperineal biopsy**

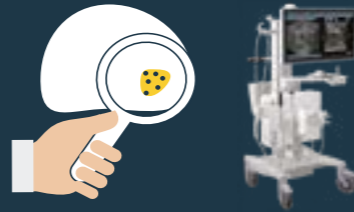BAJEAOT ET AL, EUROPEAN UROLOGY ONCOLOGY (2021)

PATIENTS



METHODS

TARGETED TRANSPERINEAL BIOPSY



RESULTS

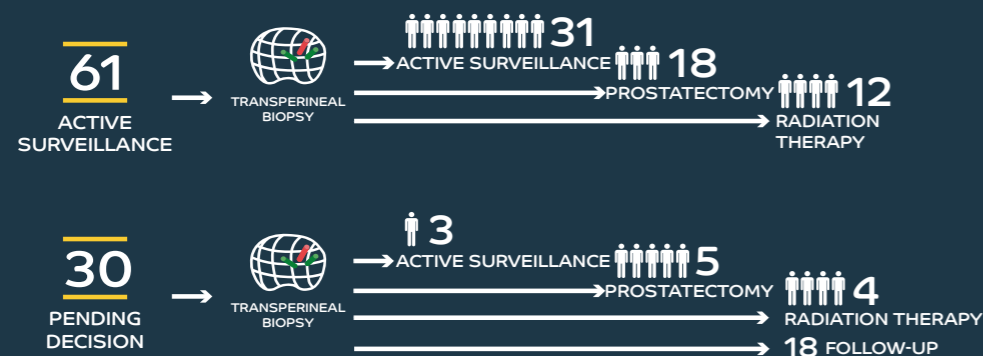
MAXIMUM CANCER CORE LENGTH (MEAN)



TOTAL CANCER CORE LENGTH (MEAN)



RISK STRATIFICATION MODIFICATION



TRANSPERINEAL BIOPSY UNDER LOCAL ANESTHESIA

INFECTION RATE AND COMPLICATIONS AFTER 621 TRANSPERINEAL MRI-TRUS FUSION BIOPSIES IN LOCAL ANESTHESIA WITHOUT STANDARD ANTIBIOTIC PROPHYLAXIS

K Günzel, A Magheli, E Baco, H Cash, S Heinrich, H Neubert, J Schlegel, M Schostak, T Henkel, P Asbach, S Hinz

¹Department of Urology, Vivantes Klinikum Am Urban Berlin, Berlin, Germany.

World J Urol 2021

PURPOSE: The aim of this study was to assess the post biopsy infection rate, feasibility and prostate cancer (PCa) detection rate (CDR) by performing transperineal MRI-TRUS fusion biopsy of the prostate (TPBx) under local anesthesia (LA) without antibiotic prophylaxis (AP).

METHODS: We prospectively screened 766 men with suspicious lesions on mpMRI, an elevated PSA level or a suspect digital examination undergoing MRI-TRUS-TPBx in LA, from May 2019 to July 2020. Patients with the need for antibiotic prophylaxis or without a PI-RADS target lesion were excluded from final analyses. We reported CDR, perioperative pain (0-10) and postoperative complications. PCa with an ISUP grade ≥ 2 was classified as clinically significant PCa (csPCa).

RESULTS: We included 621 patients with a median age of 68 years (IQR 62-74), a PSA of 6.43 ng/mL (IQR 4.72-9.91) and a prostate volume of 45 cc (IQR 32-64). In median, 4 targeted (TB) (IQR 3-4) and 6 (IQR 5-7) systematic biopsies (SB) detected in combination overall 416 (67%) PCa and 324 (52%) csPCa. Overall CDR of TB for PI-RADS 3, 4 and 5 was 26%, 65% and 84%, respectively. Patients reported a median perioperative pain level of 2 (IQR 1-3). Four patients (0.6%) developed a post biopsy infection, one experienced urosepsis.

CONCLUSIONS: Our results demonstrate that transperineal MRI-TRUS fusion-guided prostate biopsy under LA without AP is feasible, safe and well tolerated.

Infection rate and complications after 621 **transperineal MRI-trus fusion biopsies** in local anesthesia without standard antibiotic prophylaxis

GÜNZEL ET AL., WORLD JOURNAL OF UROLOGY, JANUARY 2021

PATIENTS



621

68 years

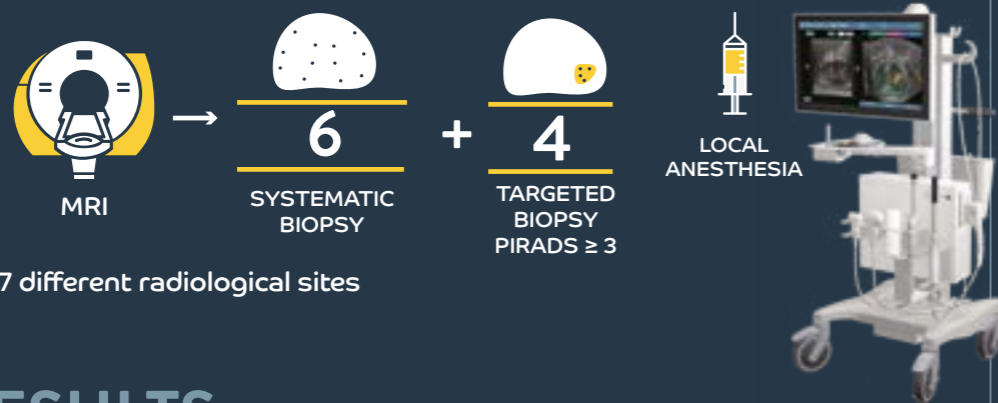
6.43 PSA ng/mL

Selected patient population:

- Elevated PSA level
- Suspect digital examination
- PI-RADS \geq 3 in mpMRI

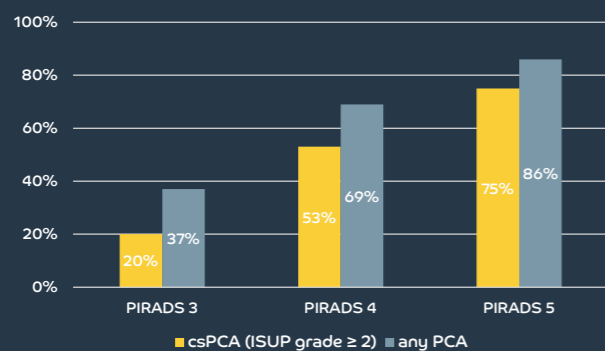
METHODS

Transperineal MRI-TRUS fusion biopsy without antibiotic prophylaxis



RESULTS

Detection of targeted and systematic biopsy



• 0.6% POST INFECTION RATE

• MEDIAN PAIN SCORE (2/10)



KEY TAKE AWAY

- MRI-TRUS fusion-guided prostate biopsy led to a significant increase in cancer detection rates
- TBx under LA are feasible with tolerable pain levels with a low infection rate in a selected patient population



BEYOND PROSTATE BIOPSY

DIAGNOSTIC ACCURACY : PET/US TARGETED BIOPSY

INCIDENTALLY DETECTED 18 F-FDG-AVID PROSTATE CANCER DIAGNOSED USING A NOVEL FUSION BIOPSY PLATFORM

Meyer A.R¹, Leroy A², Allaf M.E, Rowe S.P, Gorin M.A.

¹The James Buchanan Brady Urological Institute and Department of Urology, Johns Hopkins University School of Medicine, Baltimore, Maryland
² KOELIS®, Inc., Cambridge, Massachusetts

J Endourol Case Rep. 2019

BACKGROUND: Localized prostate cancer rarely undergoes a shift in metabolism towards aerobic glycolysis, a process known as the Warburg Effect. Because of this, positron emission tomography (PET)/CT imaging using 2-deoxy-2-[18F]fluoro-d-glucose (18F-FDG) is uncommonly used to evaluate patients with early-stage prostate cancer. However, men undergoing an 18F-FDG PET/CT for unrelated reasons will on occasion be found to have radiotracer uptake within the prostate gland. The appropriate work-up of these patients is poorly defined

CASE PRESENTATION: We present the case of a 61-year-old man with a history of tonsillar squamous cell carcinoma who was incidentally found on 18F-FDG PET/CT to have a hypermetabolic nodule within the prostate. The patient's prostate-specific antigen level was 2.1 ng/cc and digital rectal examination revealed no abnormalities. The patient underwent a targeted prostate biopsy of the lesion using the KOELIS TRINITY® biopsy platform, which uniquely allows for the real-time overlay of transrectal ultrasonography and PET/CT images. Targeted biopsy revealed Gleason score 4 + 3 = 7 (grade group 3) prostate cancer.

CONCLUSIONS: Although the incidental detection of 18F-FDG uptake within the prostate is uncommon, more than half of all patients will be found to have prostate cancer. Based on this case and our review of the available medical literature, it is our belief that men with incidentally detected uptake of 18F-FDG within the prostate should undergo further evaluation with a prostate biopsy. This recommendation is supported by data suggesting that 18F-FDG-avid prostate cancer represents a more aggressive clinical phenotype.

DIAGNOSTIC ACCURACY : PET/US TARGETED BIOPSY

FUSION TARGETED BIOPSY USING PSMA-PET/CT FOR PROSTATE CANCER DIAGNOSIS IN PATIENTS WITH A PREVIOUS NEGATIVE BIOPSY

Olivares R¹, Jofre B², González P², Velasco A, Franco C, Román C.

¹Urology Department of Clínica Santa María, Santiago, Chili

²Imaging Department of Clínica Santa María, Santiago

CAU 2018

INTRODUCTION: For patients with a previous negative biopsy but with maintained clinical suspicion for prostate cancer, Multiparametric Magnetic Resonance (MRI)-guided biopsy has demonstrated its usefulness and efficiency, especially, for the diagnosis of a clinically significant disease.

Approximately 20% of patients have lesions that are “invisible” to resonance. In these cases, PET-CT could have diagnostic usefulness with the definition of limits and guidance of the sampling during the medical procedure.

METHODS:

A 57-year-old patient
PSA level of 10ng/ml
Non suspicious DRE
Biopsy: Two previous negative biopsies
PET/CT PSMA: Two lesions with increased uptake

RESULTS:

45-minute procedure
US/PET-CT Elastic Fusion using KOELIS TRINITY® cartographer
5 targeted core samples obtained from the suspect lesions
18 additional, random cores using sextant scheme as the reference
Anatomical Pathology confirmed a Gleason score of 3+4 in 3/5 of targeted biopsy cores and in 1 among the aleatory sextant biopsy sampling

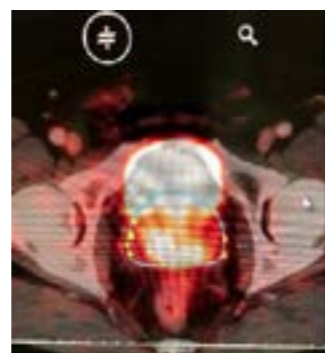


Figure 1: Two radiotracer uptakes on PSMA-PET/CT

CONCLUSIONS: First report in Latin America about the usefulness of US/PET-CT PSMA Fusion Biopsy for diagnosis of prostate cancer in a patient with previous negative biopsy and no evidence of malignancy in MRI Series involving a higher number of patients will make possible to evaluate the usefulness and the cost-effectiveness in clinical practice.

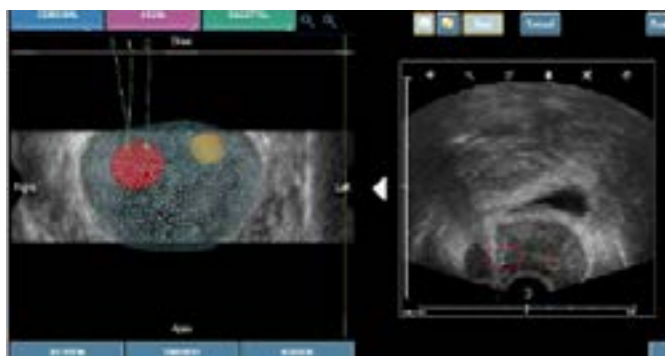


Figure 2: Targets' contour for the targeted biopsy on the US/PET-CT Fusion

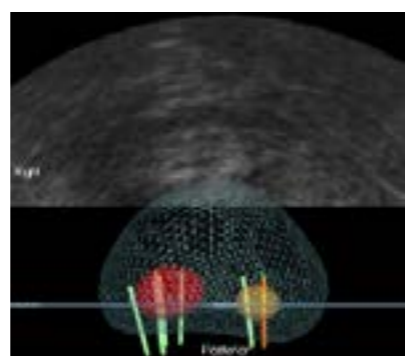


Figure 3: 3D map displaying sample cores

BEYOND PROSTATE BIOPSY

BEYOND PROSTATE BIOPSY

DIAGNOSTIC ACCURACY : PET/US TARGETED BIOPSY

TRIMODAL (18) F-CHOLINE-PET/MPMRI/TRUS TARGETED PROSTATE BIOPSIES: FIRST CLINICAL EXPERIENCE

J.L. Bonnal¹, A. Marien, A. Rock, K. El Maadarani, C. Francois, A. Delebarre, D. Berssard, B. Mauroy, P. Gosset, T. Blaire

¹Hôpital Saint Philibert, Lomme, Groupement des Hôpitaux de l'Institut Catholique de Lille

EAU 2017

PURPOSE: In this preliminary study, the feasibility of PET choline compared mpMRI was studied, to define target prostate biopsy. The fusion of these two modalities with 3D echography was to compare the diagnostic performance for primary localization of PCa with mpMRI and the latest generation of PET.

PATIENTS AND METHODS: In a prospective single-center study, from December 2014 to October 2016, all patients with PSA above 10ng/ml or patient with medical history of negative prostate biopsy were included. 3D biopsy with KOELIS® system, mpMRI and PET scan Choline were done for each patients. The biopsy targets were defined with both modalities and merging was done in real time during prostate biopsy sessions with the 3D echography. A review has been done to exclude patients with missed targets. The results were compared to anatomopathological outcome of the biopsies. Biopsy was done twice for each target at least and randomized biopsy was done outside the target.

RESULTS: 31 patients were included, mean PSA was 13.01 (5.32-73). Mean number of biopsy was 16 (13-21) and mean prostate volume was 63.41 cc (25-169). During our learning curve, 4 patients with several negative targets but 1 missed target were excluded for global analysis. However, 3 patients were detected as positive while all targets were not biopsied. Furthermore, the PET fusion analysis failed for one patient. The cancer detection rate was 69%. If the biopsy came back positive for cancer, the PET, the mpMRI or both targets were respectively positive in 72%, 94%, 100%. On average in this population the number of biopsies by target with TEP or mpMRI were respectively 1.77 (1-7), 2.74 (3-11). The TEP and IRM by target were associated with positives biopsies respectively in 43% and 62%. Compared to mpMRI, for one patient only TEP gave a positive target but fail with four other patients. mpMRI was probably best than PET choline for detecting prostate cancer but it could be complementary.

CONCLUSIONS: We demonstrate the feasibility of multiple imagery fusion with echography 3D to define localization of prostate cancer. It was very interesting to observe sometimes a great difference in the distribution of PET choline target and mpMRI target in prostate. A new study with the novel ligands targeting prostate specific membrane antigen (PSMA) could improve our clinical results.




Figure 1: The biopsy procedure was performed after registration of real-time TRUS with mpMRI and choline-PET by the same operator, using 3D TRUS-tracking system. At the time of biopsy, volume data of the mpMRI and PET 18-ch was elastically fused with TRUS. Each target was biopsied twice.

REPEAT BIOPSY FOR ACTIVE SURVEILLANCE STRATEGY

MULTIPARAMETRIC MAGNETIC RESONANCE IMAGING FACILITATES RECLASSIFICATION DURING ACTIVE SURVEILLANCE FOR PROSTATE CANCER

Fujihara A¹, Iwata T, Shakir A, Tafuri A, Cacciamani G, Gill K, Ashrafi A, Ukimura O, Desai M, Duddalwar V, Stern M, Aron M, Palmer S, Gill I, Abreu A.L.

¹ USC Institute of Urology and Catherine & Joseph Aresty Department of Urology, University of Southern California, Los Angeles, CA, USA

BJUI Inter. 2020

OBJECTIVE: To investigate the utility of multiparametric magnetic resonance imaging (mpMRI) in the reassessment and monitoring of patients on active surveillance (AS) for Grade Group (GG) 1 prostate cancer (PCa).

PATIENTS AND METHODS: We identified, from our prospectively maintained institutional review board-approved database, 181 consecutive men enrolled on AS for GG 1 PCa who underwent at least one surveillance mpMRI followed by MRI/prostate biopsy (PBx). A subset analysis was performed among 68 patients who underwent serial (at least two) mpMRI/PBx during AS. Pathological progression (PP) was defined as upgrade to GG ≥ 2 on follow up biopsy.

RESULTS: Baseline MRI was performed in 34 patients (19%). At a median follow-up of 2.2 years for the overall cohort, the PP was 12% (6/49) for Prostate Imaging Reporting and Data System (PI-RADS) 1–2 lesions and 37% (48/129) for the PI-RADS ≥ 3 lesions. The 2-year PP-free survival rate was 84%. Surveillance prostate-specific antigen density ($P < 0.001$) and surveillance PI-RADS ≥ 3 ($P = 0.002$) were independent predictors of PP on reassessment MRI/PBx. In the serial MRI cohort, the 2-year PP-free survival was 95% for the No-MRI-progression group vs 85% for the MRI-progression group ($P = 0.02$). MRI progression was significantly higher in the PP (62%) than in the No-PP (31%) group ($P = 0.04$). If serial MRI were used for PCa surveillance and biopsy were triggered based only on MRI progression, 63% of PBx might be postponed at the cost of missing 12% of GG ≥ 2 PCa in those with stable MRI. Conversely, this strategy would miss 38% of those with upgrading to GG ≥ 2 PCa on biopsy. Stable serial mpMRI correlates with no reclassification to GG ≥ 3 PCa during AS.

CONCLUSIONS: On surveillance mpMRI, PI-RADS ≥ 3 was associated with increased risk of PCa reclassification. Surveillance biopsy based only on MRI progression may avoid a large number of biopsies at the cost of missing many PCa reclassifications.

BEYOND PROSTATE BIOPSY

BEYOND PROSTATE BIOPSY

REPEAT BIOPSY FOR ACTIVE SURVEILLANCE STRATEGY

PERFORMANCE OF SYSTEMATIC, MRI-TARGETED BIOPSIES ALONE OR IN COMBINATION FOR THE PREDICTION OF UNFAVOURABLE DISEASE IN MRI-POSITIVE LOW-RISK PROSTATE CANCER PATIENTS ELIGIBLE FOR ACTIVE SURVEILLANCE

Ploussard G¹, Beauval J-B, Lesourd M, Almeras C, Assoun J, Aziza R, Gautier J-R, Loison G, Portalez D, Salin A, Tollon C, Soulié M, Malavaud B, Roumiguié M.

¹Department of Urology, La Croix du Sud Hospital, IUCT-O, Toulouse, France

World Journ Urol. 2019

PURPOSE: To assess the upstaging/upgrading rates of low-risk prostate cancer (PCa) according to the biopsy scheme used (systematic (SB), targeted biopsies (TB), or both) in the setting of positive pre-biopsy MRI.

PATIENTS AND METHODS: We included 143 consecutive men fulfilling the Toronto University active surveillance (AS) criteria who underwent a pre-biopsy positive MRI, a combination of SB and software-based fusion TB, and a radical prostatectomy, in two expert centres. The primary endpoints were the pathological upgrading and upstaging rates. Overall unfavourable disease (OUD) was defined by any pT3-4 and/or pN1 and/or \geq GG 3.

RESULTS: Using TB alone would have missed 21.7% of cancers including 16.7% of \geq GG 3. The use of TB was significantly associated with a lower risk of \geq Grade Group (GG) 3 disease ($p < 0.006$) in RP specimens. Combination of SB and TB lowered this risk by 39%, compared with TB alone. The biopsy scheme did not affect the upstaging rates which were substantial even in case of combination scheme (from 37 to 46%). OUD was detected in approximately 50% of cases. The presence of high grade on TB was the only independent predictive factor for both \geq GG 2 ($p = 0.015$) and \geq GG 3 ($p = 0.023$) in RP specimens.

CONCLUSIONS: High grade on TB biopsies represented the major predictor of upgrading. Combination of SB and TB better defined the sub-group of patients having the lowest risk of reclassification, compared with TB or SB alone. The risk of non-organ-confined disease remained high, and could not be accurately predicted by MRI or systematic/targeted biopsy features.

REPEAT BIOPSY FOR ACTIVE SURVEILLANCE STRATEGY

A NOVEL TECHNIQUE USING THREE-Dimensionally DOCUMENTED BIOPSY MAPPING ALLOWS PRECISE RE-VISITING OF PROSTATE CANCER FOCI WITH SERIAL SURVEILLANCE OF CELL CYCLE PROGRESSION GENE PANEL

Ukimura O¹, Gross ME, de Castro Abreu AL, Azhar RA, Matsugasumi T, Ushijima S, Kanazawa M, Aron M, Gill IS.

¹USC Institute of Urology, Keck School of Medicine, University of Southern California, Los Angeles, California.

The Prostate. 2015

BACKGROUND: Conventional systematic biopsy has the shortcoming of sampling error and reveals «no evidence of cancer» with a rate of >50% on active surveillance (AS). The objective of this study is to report our initial experience of applying a 3D-documented biopsy-mapping technology to precisely re-visit geographically documented low-risk prostate cancer and to perform serial analysis of cell-cycle-progression (CCP) gene-panel.

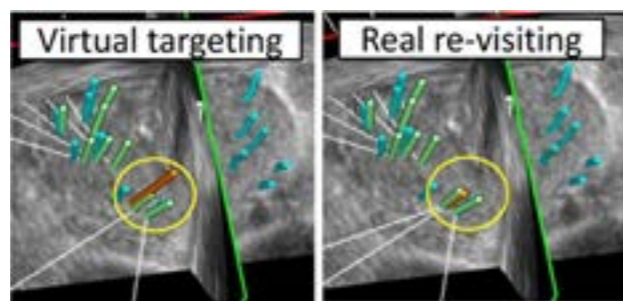


Figure 1. The re-visiting biopsy technique using the pair of “virtual” and “real” targeting. The re-visiting biopsy technique is demonstrated in Figure 2 by the pair of “virtual” (long orange trajectory, circled in yellow in the left of Fig. 3) and “real” biopsies (short orange trajectory, circled in yellow in the right of Fig. 2), intentionally sampling from the previously positive targets in the location of the right-apex-medial. Because the virtual targeting seemed 3–4 mm too lateral to reach the target, the direction of the real biopsy was further corrected to bring it closer to the target. Note that one core (green trajectory) had already been sampled during the current 2nd-look biopsy from the same positive target with the same re-visiting technique. These two re-visiting cores in the 2nd look biopsy were positive for cancer. The overlaid image demonstrates that the pair of green and orange trajectories of the re-visiting technique almost corresponded (or were located within 1–2 mm) with the blue trajectory of the positive core at the right-apex-medial on the 1st-look biopsy.

METHODS: Over a period of 40 months (1/2010-4/2013), the 3D-biopsy-mapping technique, in which the spatial location of biopsy-trajectory was digitally recorded (KOELIS®), was carried out. A pair of diagnostic (1st-look) and surveillance (2nd-look) biopsies were performed per subject (n=25), with median interval of 12 months. The documented biopsy-trajectory was used as a target to guide the re-visiting biopsy from the documented cancer focus, as well as the targeted field-biopsy from the un-sampled prostatic field adjacent to negative diagnostic biopsies. The accuracy of re-visiting biopsy and biopsy-derived CCP signatures were evaluated in the pair of the serial biopsy-cores.

RESULTS: The 1st-look-biopsy revealed a total of 43 cancer lesions (1.7 per patient). The accuracy of re-visiting cancer was 86% (37/43) per lesion, 76% (65/86) per core, and 80% (20/25) per patient. This technology also provided an opportunity for 3D-targeted field-biopsy in order to potentially minimize sampling errors. The CCP gene-panel of the 1st-look (-0.59) versus 2nd-look (-0.37) samples had no significant difference (P=0.4); which suggested consistency in the molecular signature of the known cancer foci during the short-time interval of median 12 months. Any change in CCP of the same cancer foci would be likely due to change in sampling location from the less to more significant portion in the cancer foci rather than true molecular progression. The study limitations include a small number of the patients.

CONCLUSIONS: The 3D-documented biopsy-mapping technology achieved an encouraging re-sampling accuracy of 86% from the known prostate cancer foci, allowing the serial analysis of biopsy-derived CCP signatures.

BEYOND PROSTATE BIOPSY

BEYOND PROSTATE BIOPSY

REPEAT BIOPSY FOR ACTIVE SURVEILLANCE STRATEGY

VALIDATION OF THE EUROPEAN SOCIETY OF UROGENITAL RADIOLOGY SCORING SYSTEM FOR PROSTATE CANCER DIAGNOSIS ON MULTIPARAMETRIC MAGNETIC RESONANCE IMAGING IN A COHORT OF REPEAT BIOPSY PATIENTS

Portalez D¹, Mozer P, Cornud F, Renard-Penna R, Misrai V, Thoulouzan M, Malavaud B.

¹Department of Radiology, Clinique Pasteur, Toulouse, France

World Journ Urol. 2019

BACKGROUND: Wide variations in acquisition protocols and the lack of robust diagnostic criteria make magnetic resonance imaging (MRI) detection of prostate cancer (PCa) one of the most challenging fields in radiology and urology.

DESIGN, SETTING, AND PARTICIPANTS: An institutional review board-approved multicentric prospective study; 129 consecutive patients (1514 cores) referred for mpMRI after at least one set of negative biopsies.

INTERVENTION: Transfer of mpMRI-suspicious areas on three-dimensional (3D) transrectal ultrasound images by 3D elastic surface registration; random systematic and targeted cores followed by core-by-core analysis of pathology and mpMRI characteristics of the core locations. The ESUR scores were assigned after the procedure on annotated Digital Imaging and Communications in Medicine archives.

OUTCOME MEASUREMENTS AND STATISTICAL ANALYSIS: Relationships between ESUR scores and biopsy results were assessed by the Mann-Whitney U test. The Yates correction and Pearson χ^2 tests evaluated the association between categorical variables. A teaching set was randomly drawn to construct the receiver operating characteristic curve of the ESUR score sum (ESUR-S). The threshold to recommend biopsy was obtained from the Youden J statistics and tested in the remaining validation set in terms of sensitivity, specificity, positive predictive value, negative predictive value, and accuracy.

RESULTS AND LIMITATIONS: Higher T2-weighted, dynamic weighted imaging and dynamic contrast-enhanced ESUR scores were observed in areas yielding cancer-positive cores. The proportion of positive cores increased with the ESUR-S aggregated in five increments (ESUR-S 3-5: 2.9%; ESUR-S 6-8: 11.1%; ESUR-S 9-10: 38.2%; ESUR-S 11-12: 63.4%; and ESUR-S 13-15: 83.3%; p<0.0001). A threshold of ESUR-S ≥ 9 exhibited the following characteristics: sensitivity: 73.5%; specificity: 81.5%; positive predictive value: 38.2%; negative predictive value: 95.2%; and accuracy: 80.4%. Although the study was not designed to compare repeat biopsy strategies, more targeted cores than random systematic cores were found to be positive for cancer (36.3% compared with 4.9%, p<0.00001).

CONCLUSIONS: In the challenging situation of repeat biopsies, the ESUR scoring system was shown to provide clinically relevant stratification of the risk of showing PCa in a given location.

FOCAL TREATMENT

A NOVEL FOCAL THERAPY – MICROWAVE ABLATION UNDER ORGAN-BASED TRACKING (OBT) FUSION IN PATIENTS WITH LOCALIZED PROSTATE CANCER: PRELIMINARY RESULTS OF FOSTINE 01B PILOT STUDY

Peltier A¹, Assenmacher G, Aoun F, Hawaux E, Limani K, Sirtaine N, Ben Aziz M, Lefebvre Y, Lemort M, Van Velthoven R.

¹ Institut Jules Bordet, Departement of Urology, Brussels, Belgium

Eur Urol Open Sci. 2020

INTRODUCTION ET OBJECTIVES: Through an ablate-and-resect study, we evaluated the feasibility, safety and histological effects of very low loss (VLL) microwave ablation, performed transrectally under real-time MRI/TRUS image registration and 3D mapping, in patients with localized prostate cancer (PCa).

MATERIALS AND METHODS: Patients with a detectable index lesion on mpMRI, PSA level <20 ng/mL and wishing to undergo a prostatectomy in case of significant PCa on biopsy were eligible for this study approved by Ethics Committee. Targeted biopsies of the index lesion were performed by using an ultrasound-MRI image fusion system with OBT-registration (KOELIS TRINITY®, KOELIS®, France) to provide quality control. Targeted cores were analyzed intraoperatively with an extemporaneous analysis. If positive, the patients were treated during the same session by a targeted focal microwave ablation using a single 18G needle inserted transrectally under sedation. Predictive ablation charts obtained with the microwave generator (TATO, Biomedical Srl, Italy) through in vitro experiments were used to choose the duration and power of the treatment. Treated patients were followed-up for 4 to 6 weeks and the planned radical prostatectomy was performed. All patients underwent uroflowmetry test and filled the self-administered questionnaires (IPSS, IPSS-QOL, IIEF-5, and MSHQ-EjD-SF) before the intervention, at 7 days and 1 month after the procedure. A mpMRI of the treated prostate was performed at 7 days. After radical prostatectomy, whole-mount histology served to define the ablation boundaries and dimensions in the prostate. A total of 10 patients will be operated.

RESULTS: From January to June 2019, 5 patients participated in this ablate-and-resect study without therapeutic intent. Microwave ablation was performed on 4 patients. One patient did not receive the treatment due to negative targeted biopsies and was exited from the study. Another one withdrew his consent after microwave ablation and thus did not undergo radical prostatectomy. He is now under active surveillance. All procedures were performed under sedation in an outpatient setting, with a median intervention time of 81.5 min [63.75-96.5]. After 4 interventions, no patient reported any pain and no serious adverse event was observed. The early postoperative mpMRI showed consistent devascularization on the T1 DCE MRI at the treatment site. A sharp necrosis was also observed on the whole-mount sections. Further interventions will allow to compare clinical observations with the predictive charts.

CONCLUSIONS: Our pilot study demonstrated that microwave ablation guided by OBT-fusion in patients with localized PCa is safe, feasible and easily deliverable in an outpatient setting. Histopathological analyses confirm a well-delimited ablation shape.

BEYOND PROSTATE BIOPSY

BEYOND PROSTATE BIOPSY

FOCAL TREATMENT

TRAITEMENT FOCAL TRANSRECTAL PAR MICRO-ONDE DU CANCER DE LA PROSTATE LOCALISÉ DE RISQUE FAIBLE ET INTERMÉDIAIRE : RÉSULTATS PRÉLIMINAIRES

Barry Delongchamps N¹, Schull A, Saighi D, Zerbib M, Peyromaure M.

¹Hôpital Cochin, Paris, France

Progrès en Urol. 2019

OBJECTIFS: L'objectif de cette étude était de tester la faisabilité, la précision et la sécurité d'un traitement transrectal de la tumeur index par micro-onde, guidée par fusion d'image élastique IRM-échographie, chez 10 patients ayant un cancer de la prostate de risque faible ou intermédiaire.

MÉTHODES: Les patients éligibles devaient avoir un PSA < 15 ng/mL, une tumeur index à plus de 5 mm du rectum, et ayant un score de Gleason ≤ 3 + 4. Le système de guidage par cartographie 3D KOELIS TRINITY® (KOELIS®) était utilisé pour le diagnostic, le traitement et le suivi. Un applicateur de 18G délivrait les micro-ondes par voie transrectale sous anesthésie générale. Le critère d'évaluation principal était la nécrose complète du volume cible sur l'IRM à j7. Les critères d'évaluation secondaire étaient la tolérance urinaire et sexuelle. Des biopsies ciblées étaient réalisées dans la zone traitée à 6 mois.

RÉSULTATS: Les caractéristiques cliniques et carcinologiques sont résumées dans les Tableau 1, Tableau 2. La totalité des patients ont pu être traités selon le protocole. La durée moyenne de l'anesthésie générale était de 82 (44-170) minutes. Aucune douleur ni aucun autre effet indésirable n'a été observé en postopératoire immédiat et pendant la durée de l'étude. Les mictions ont repris de manière spontanée dans les deux heures suivant l'intervention. À j7, le volume de nécrose recouvrait totalement le volume cible chez 8 (80 %) patients. Après un suivi de 6 mois, aucune modification des scores IPSS et IIEF5 n'a été observée (Tableau 3). Les biopsies réalisées dans la zone présumée traitée montraient la persistance de cancer de Gleason 3 + 3 et 3 + 4 chez 3 (30 %) et 2 (20 %) patients, respectivement.

CONCLUSIONS: Ces résultats suggèrent que le traitement transrectal par micro-onde guidé par fusion d'image IRM-échographie est faisable, précis et bien toléré. Plus de patients sont nécessaires pour mieux évaluer le résultat carcinologique à long terme.

3D TARGETED FOCAL CRYOTHERAPY TREATMENT: CASE REPORT OF THE FIRST PROCEDURE AT OUR INSTITUTION

S. Crouzet¹, P. Moldovan²

¹ Department of Urology, Radiology
²Hôpital Edouard Herriot, Lyon, France

Poster FTI 2019

INTRODUCTION : Focal treatment is an emerging solution, which yields high interest as an optimal compromise between radical treatment and active surveillance. Nevertheless, this approach requires, in addition to a focally applied energy, an adequate targeting to properly place the energy. The feasibility of focal targeted cryotherapy using a fusion and mapping platform is here investigated on a patient.

METHODS AND MATERIALS: A 71-years-old patient with a chemical recurrence following external beam radiotherapy for prostate cancer, with suspicious foci identified on Choline-PET scan and confirmed by transrectal-targeted biopsy gave consent to receive a targeted and focal cryotherapy treatment. No other tumor site demonstrated on complete workup. The patient was contraindicated for HiFu treatment (rectal stenosis following the initial treatment). A 3D multimodal cartographer (KOELIS TRINITY®, KOELIS®, Meylan, France) and associated accessories (PERINE™ 3D motorized ultrasound probe, STEADYPRO™ mechanical probe holder and needle guides) were used to delineate the region to be treated (MRI/PET-CT/transrectal ultrasound fusion), to guide the cryoprobes implantation and to monitor the focal treatment performed under transperineal access. The cryotherapy system (Visuallce system and IceSphere cryoprobes, GALIL, Arden Hills ,USA) delivered the cryotherapy treatment. Two cryoprobes were placed in the region of interest to be treated under 3D guidance, as well as one thermosensor in the recto-prostatic fascia.

RESULTS: Planning, targeting, and monitoring have been done successfully. The targeting procedure, from the beginning of the fusion to the end of the implantation, lasted 27 minutes and the treatment 33 minutes. 3D ultrasound imaging was used during the procedure to confirm treatment delivery in the targeted area. No pain or adverse effects have been reported. The real-time mapping capacities of the cartography system allowed to guide the cryoprobes in the anatomical volume, improving accuracy and speeding up the procedure. All the treatment information has been gathered in a 3D prostate map which will allow an effective follow-up of the patient.

CONCLUSIONS: Targeted focal cryotherapy using 3D cartography is feasible and allows to plan, guide, monitor and record such a treatment with precision and safety. This tool will be used in clinical routine at our institution.

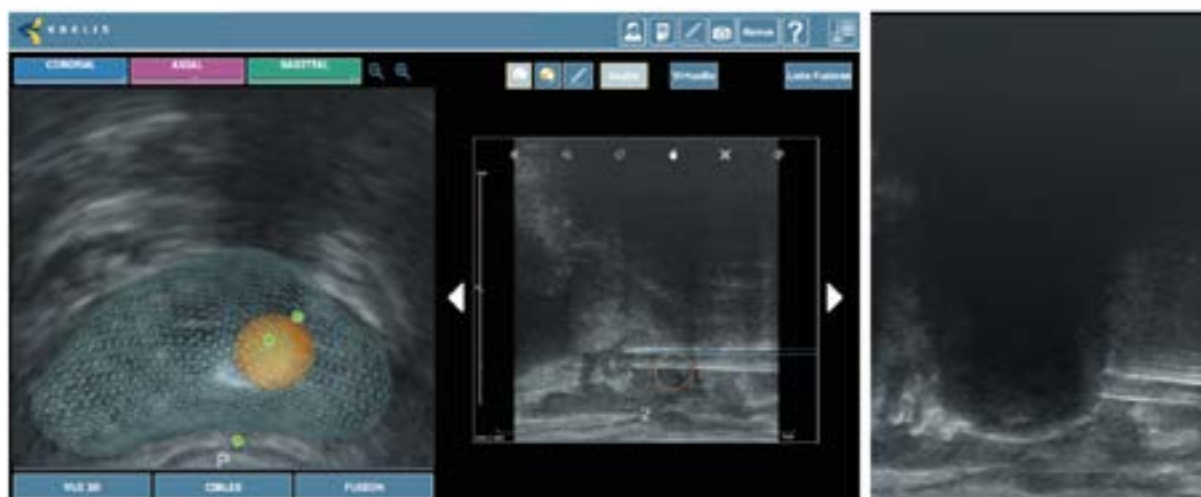


Figure 1: The real-time mapping capacities of the cartography system allowed to guide the cryoprobes in the anatomical volume.

BIBLIOGRAPHY

2019 – Roumiguie M et al. – Improvement of the intermediate risk prostate cancer sub-classification by integrating MRI and fusion biopsy features 4

2018 – Oderda M et al. – Int J Urol – Accuracy of elastic fusion biopsy in daily practice: Results of a multicenter study of 2115 patients.....5

2018 – Rouvière O et al. – Lancet Oncol – Use of prostate systematic and targeted biopsy on the basis of multiparametric MRI in biopsy-naive patients (MRI-FIRST): a prospective, multicenter, paired diagnostic study7

2018 – Kasivisvanathan V et al. – NEJM – MRI-targeted or standard biopsy for prostate-cancer diagnosis 8

2017 – Shin T et al. – BJU Int – Detection of prostate cancer using magnetic resonance imaging/ultrasonography fusion targeted biopsy in African American men 9

2016 – Baco E et al. – Eur Urol – A randomized controlled trial to assess and compare the outcomes of two-core prostate biopsy guided by fused magnetic resonance and transrectal ultrasound images and traditional 12-core systematic biopsy 10

2016 – Klein J et al. – Urol Int – Transrectal ultrasound-guided prostate biopsy for cancer detection: performance of 2D, 3D and 3D-MRI fusion targeted techniques.....11

2015 – Renard Penna R et al. – Radiology – Prostate imaging reporting and data system and LIKERT scoring system: multiparametric MR imaging validation study to screen patients for initial biopsy 12

2014 – Mozer P et al. – BJUI – First round of targeted biopsies using magnetic resonance imaging/ultrasonography fusion compared with conventional transrectal ultrasonography-guided biopsies for the diagnosis of localised prostate cancer13

2021 – Lenfant L et al. – Progrès en Urologie – Évaluation sur 10 ans des biopsies ciblées pour le diagnostic du cancer de la prostate : une étude monocentrique prospective 14

2021 – Kaneko M et al. – Current Urology Report – Techniques and Outcomes of MRI-TRUS Fusion Prostate Biopsy 16

2013 – Peltier A et al. – Hindawi – 3D versus 2D systematic transrectal ultrasound-guided prostate biopsy: higher cancer detection rate in clinical practice17

2009 – Mozer P et al. – J US Med –Mapping of transrectal ultrasonographic prostate biopsies: quality control and learning curve assessment by image processing 18

2018 – Cornud F et al. – Radiology – Precision matters in MR imaging-targeted prostate biopsies: evidence from a prospective study of cognitive and elastic fusion registration transrectal biopsies 19

2013 – Cornud F et al. – Abdom Imaging – TRUS-MRI image registration: a paradigm shift in the diagnosis of significant prostate cancer21

2020 – Jacewich M et al. – Multicenter transperineal MRI-TRUS fusion guided outpatient clinic prostate biopsies under local anesthesia 22

"Health innovation as a passion"

KOELIS®, has assisted urologists and radiologists from around the world in their routine clinical practice since 2006, providing the latest technology for personalized prostate cancer planning and management, from fusion biopsy to active surveillance and prostate treatment.

Focused on developing advanced, targeted and less invasive solutions, KOELIS® is committed to creating and bringing to the market a new paradigm in prostate cancer care, where physicians can offer the most personalized answers to their patients, avoiding any under or overtreatment and preserving quality of life. Thanks to cutting-edge imaging tools like KOELIS TRINITY® prostate fusion biopsy system, which combines multiple imaging modalities with full 3D ultrasound and Organ-Based Tracking Fusion®, any suspicious lesion is characterized in a detailed 3D prostate map, offering a comprehensive and multiparametric approach and enhancing diagnostic confidence.

The team at KOELIS® innovates every day in collaboration with world-renowned universities and hospitals to offer physicians new advancements in imaging and a greater field of view, a must-have in active surveillance and targeted treatment. Based in France (Grenoble), Princeton (New Jersey), Germany (Saarbrücken) and Asia, KOELIS® technology has been featured in more than 70 clinical publications and treats more than 300,000 patients worldwide, including patients in Europe, United States, Canada, Japan, Australia, South America and the Middle East.

KOELIS SAS

22 chemin du Vieux Chêne
38240 Meylan (Grenoble) - France

KOELIS Inc. USA

116 Village Boulevard Suite 308
Princeton, NJ 08540, United States

KOELIS GmbH

Postfach 10 05 43
66005, Saarbrücken - Germany

 www.koelis.com KoelisBx KOELIS Koelis